

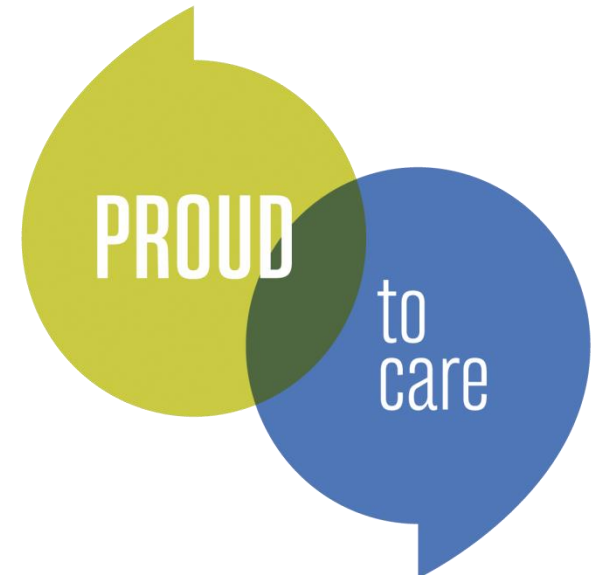# Endoscopic Ultrasound, What you need to know

Dr. Hussam Ahmed

Consultant Gastroenterologist

Barnsley & Rotherham General Hospitals

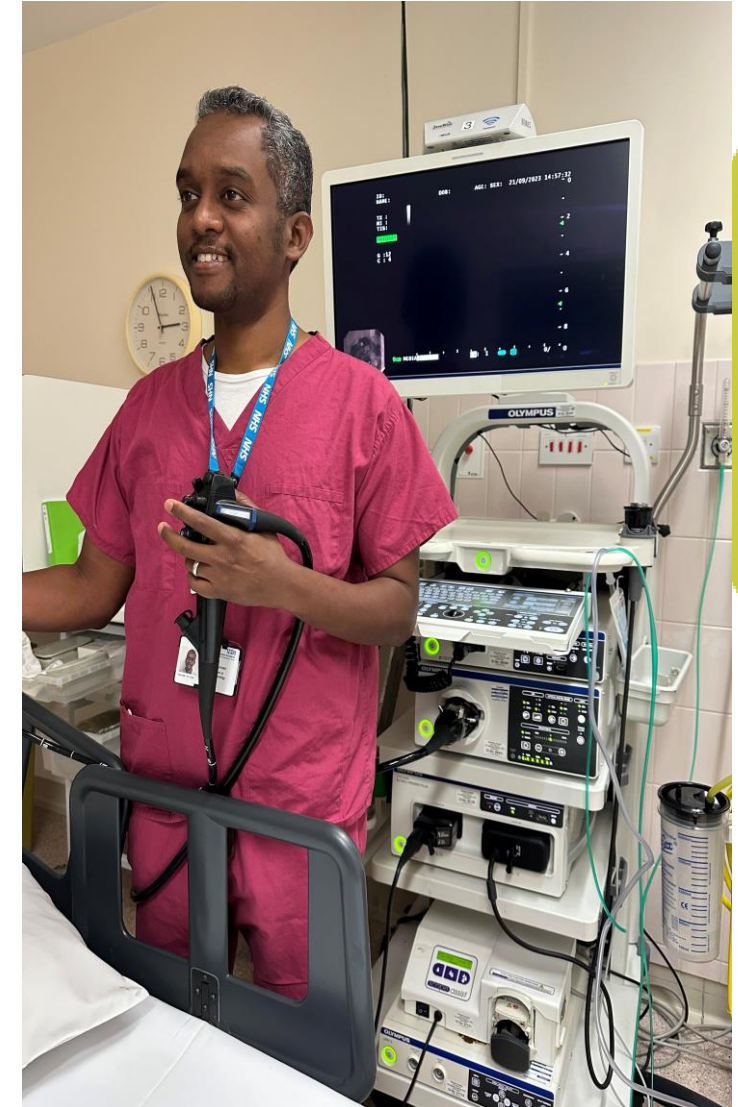15 Nov 2023



- What is EUS
- Why EUS
- EUS adjuncts
- Indications
- Side effects and complications
- What you need to know from GP perspective

# What is EUS

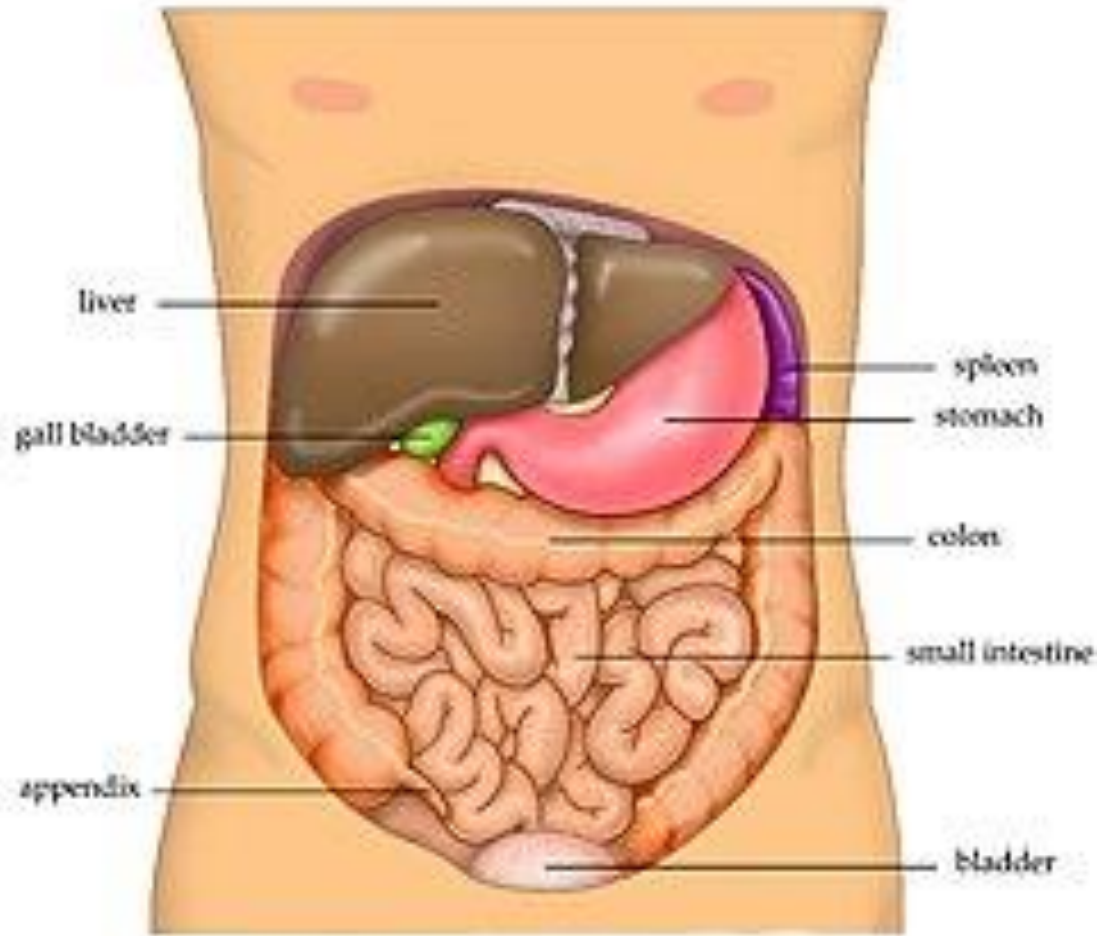
- Minimal invasive specialised endoscopic procedure to evaluate lining of the GIT and nearby organs/structures/tissues.
- Procedure combines both Endoscopy and US
- Flexible tube and US device that use soundwaves to create detail images
- Types: Radial & linear





# Why EUS

- Why not transabdominal or CT-scan?

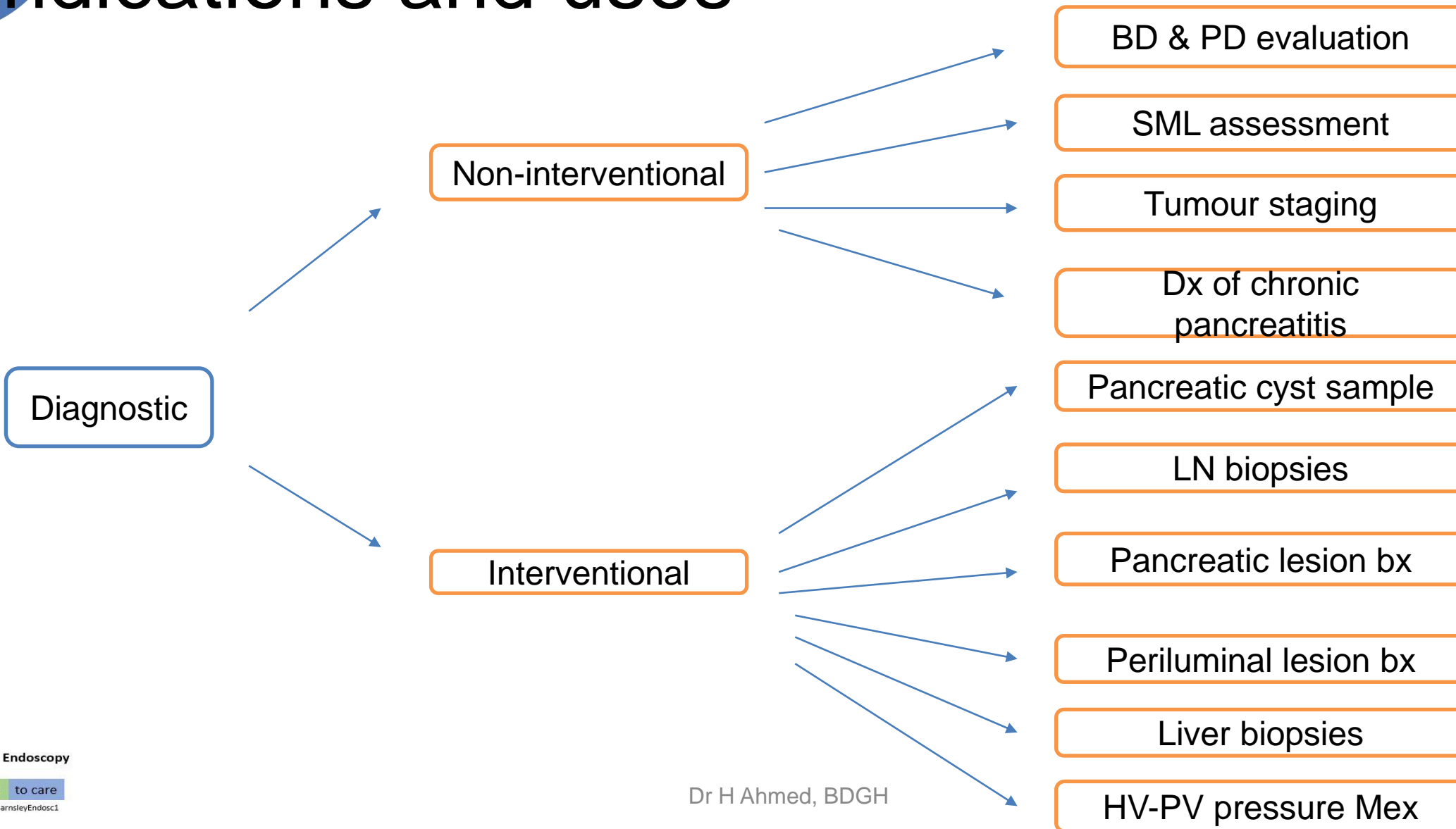


Courtesy of Wikipedia Free  
Encyclopaedia

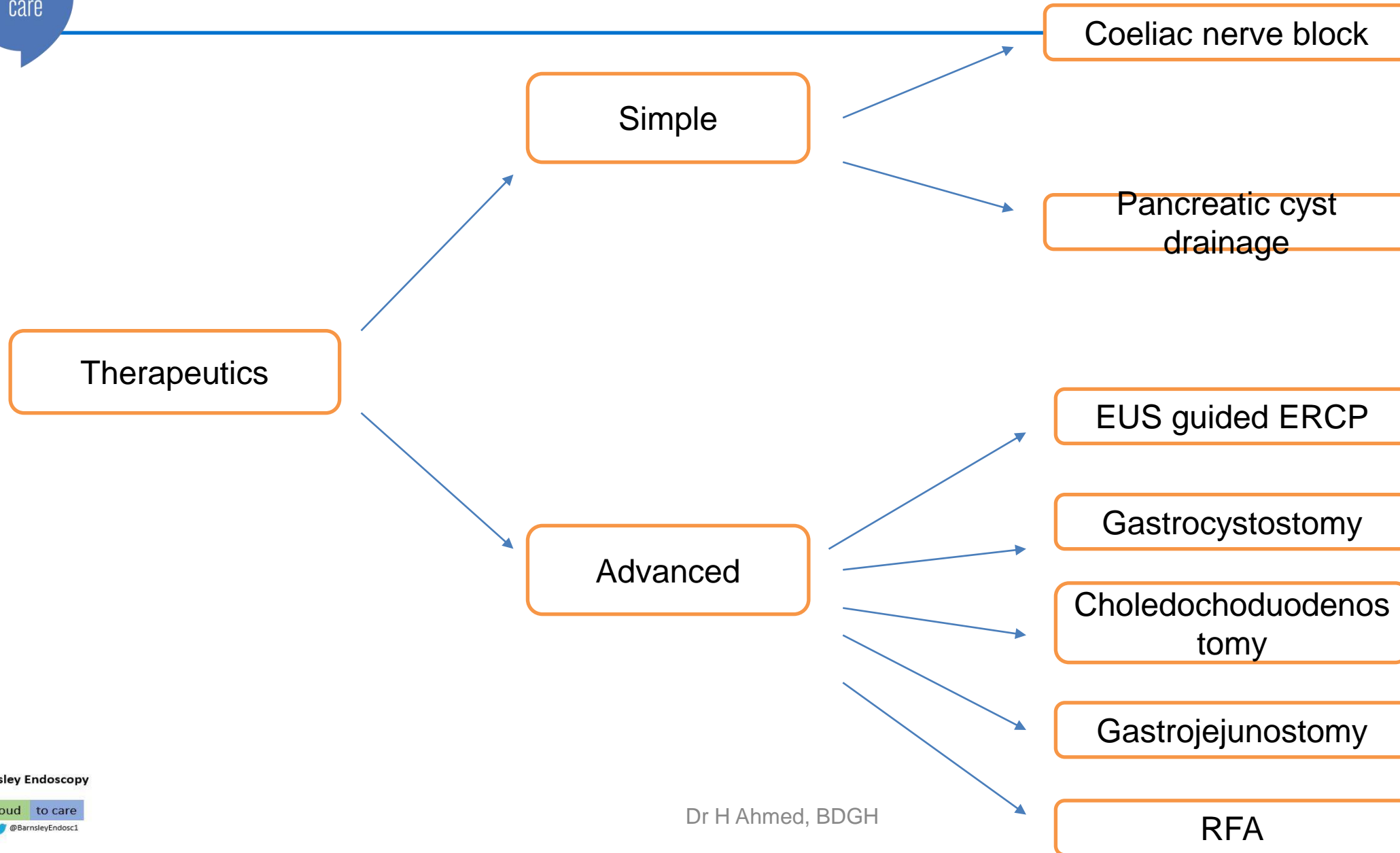




# Indications and uses



Dr H Ahmed, BDGH





# EUS adjuncts and equipment

- FNA/FNB needles (Boston)
- Balloon
- Stents
- Contrast

# FNB needle



Courtesy of [BostonScientific.com](https://www.bostonscientific.com)

Dr H Ahmed, BDGH

# FNA needle



Courtesy of [BostonScientific.com](https://www.bostonscientific.com)

Dr H Ahmed, BDGH

# Case 1

- 73 M
- STT with dyspepsia & weight loss
- OGD – Unremarkable
- CT- scan – Advanced TOP lesion
- Referred for EUS +/- FNB

ID:  
NAME:

DOB:

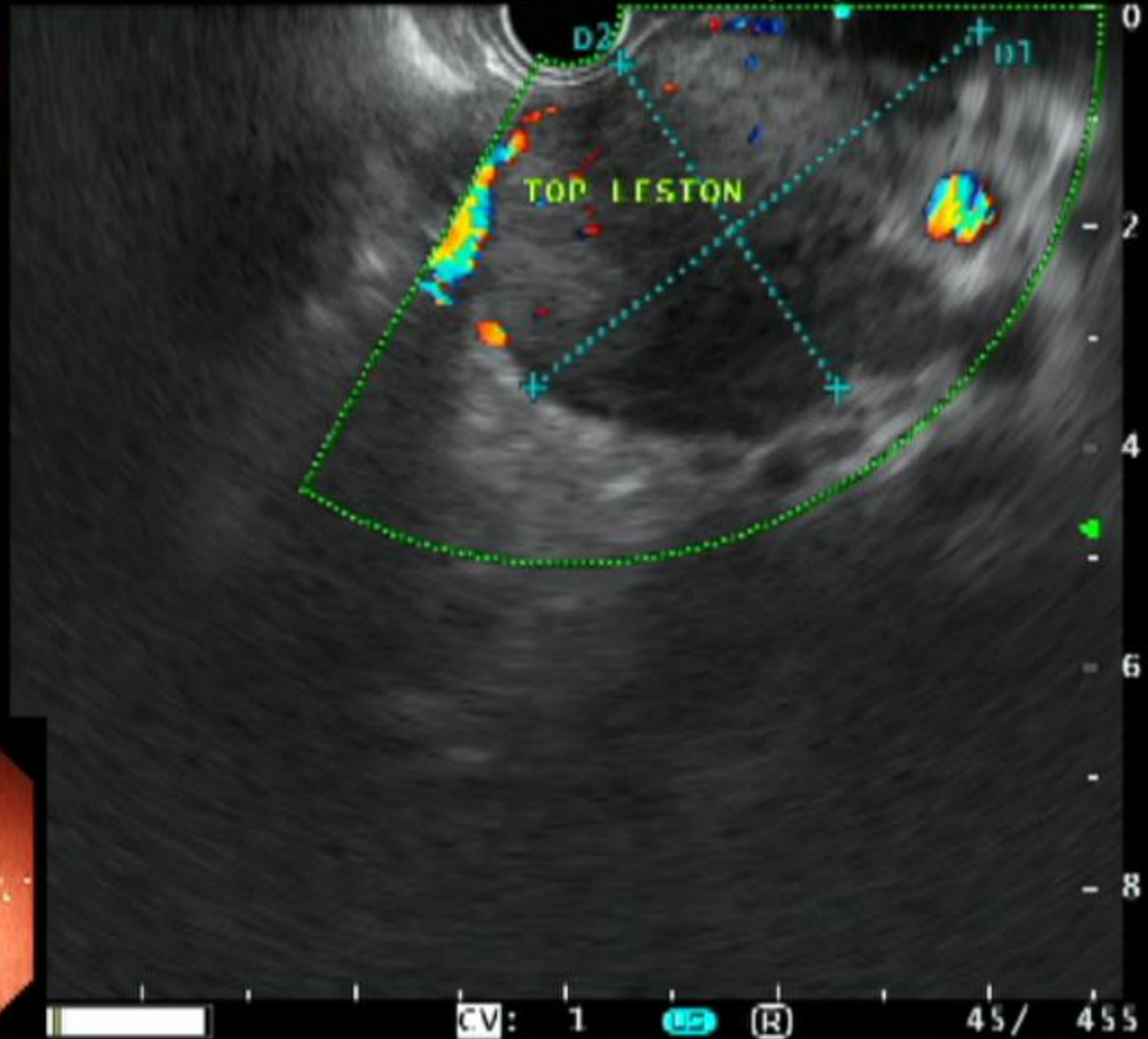AGE: SEX: 12/10/2023 16:08:54

TX :100%  
MI :0.6  
TIS:<0.4

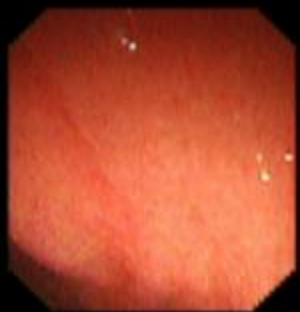

7.5MHz

G :15  
C : 5  
FG:19



D1: 53.2mm



CV: 1 (R) 45/ 455

ID:  
NAME:

DOB:

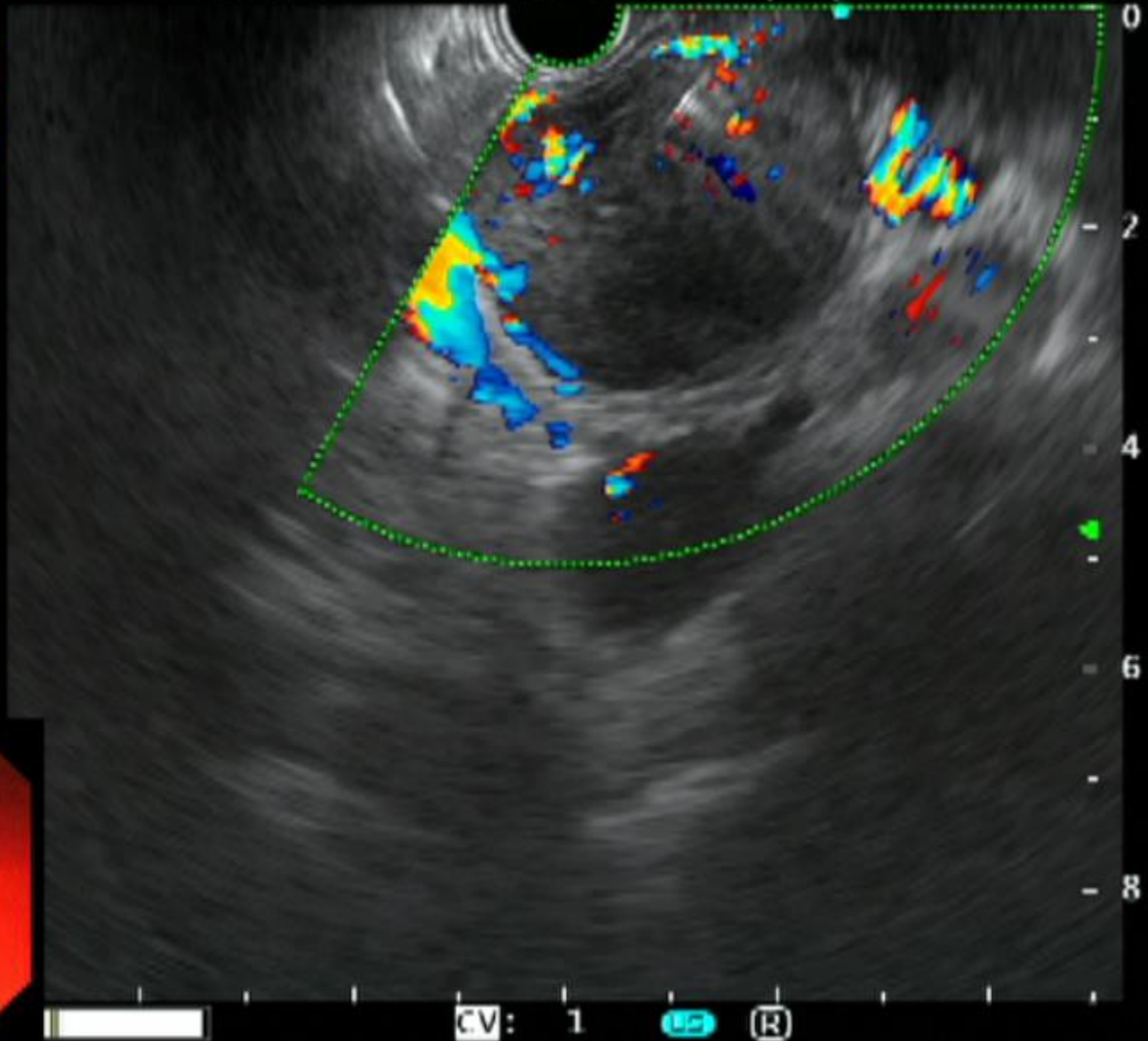
AGE: SEX: 12/10/2023 16:11:19

TX :100%  
MI :0.6  
TIS:<0.4



7.5MHz

G :15  
C : 5  
FG:19



# Case 2

- 21M
- Abdominal pain and bloating
- OGD
- Small Gastric SML
- Referred for EUS +/- FNB



ID: ■  
Name:

Sex:    Age:  
D.O.B.:  
07/11/2023  
15:27:59

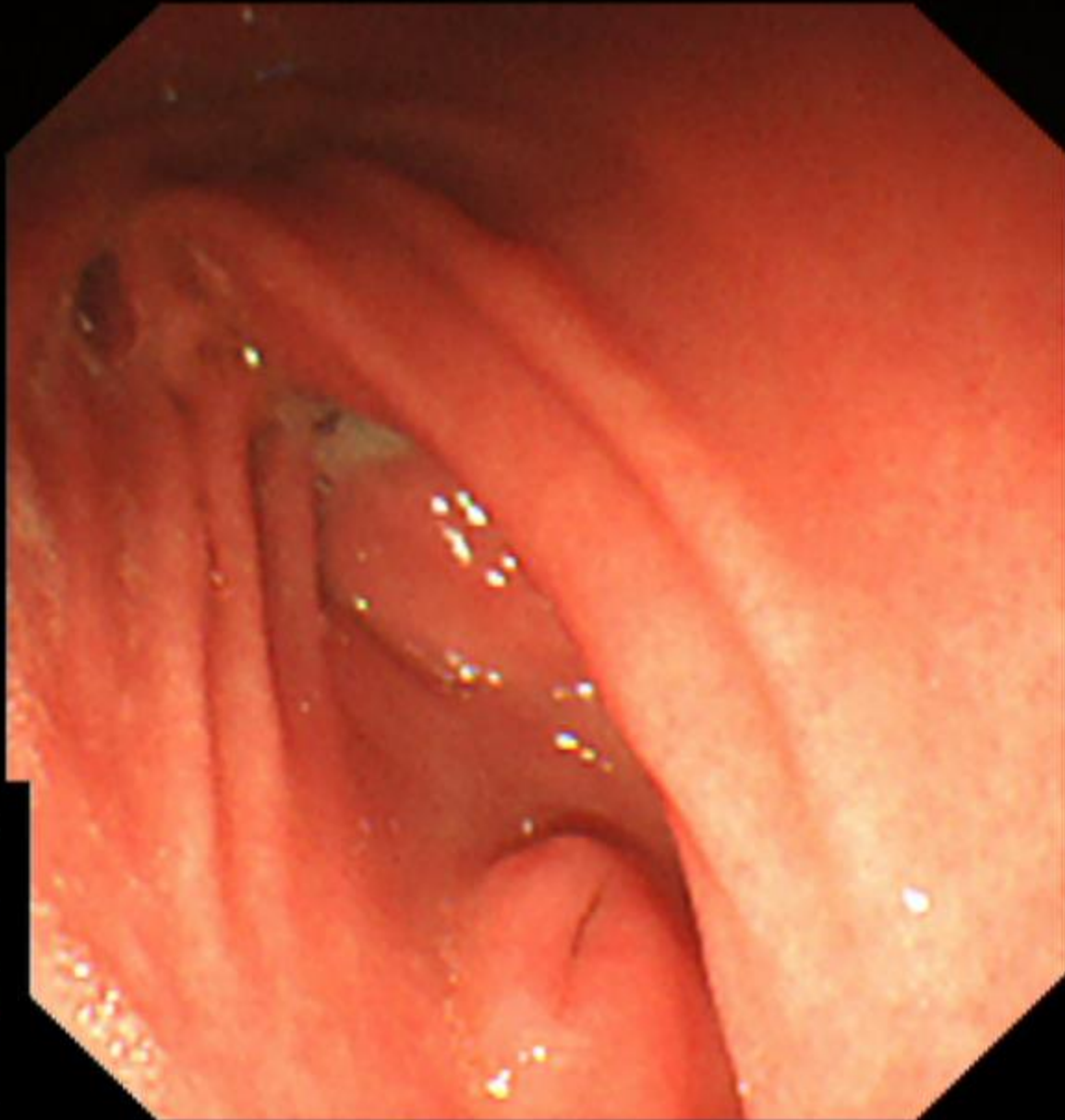■■■■/---

0/1

Fh:A1 Cm:0



Endoscopic navigation system overlay showing a 2D map of the colon and a 3D depth map. The 2D map shows the current position of the endoscope (indicated by a red arrow) and the overall path. The 3D map shows the depth of the colon wall. Text labels include 'Fh:A1 Cm:0' and 'Comment:'. There are also some small icons and numbers at the bottom of the overlay.



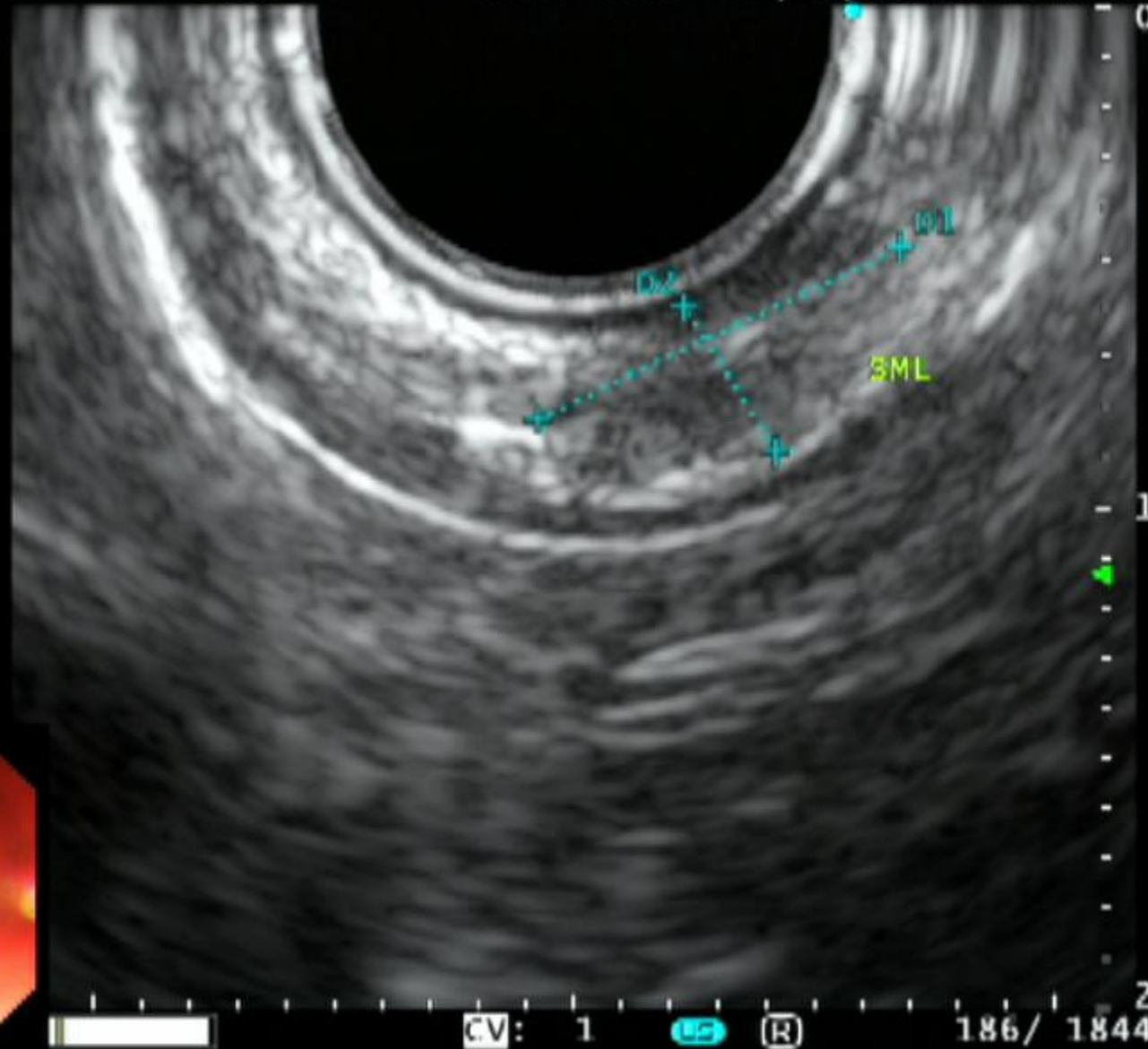


ID: NAME: DOB: AGE: SEX: 02/11/2023 15:40:08

TX :100%  
MI :0.6  
TIS:<0.4

7.5MHz

G :15  
C : 5



D1: 8.3mm

CV: 1 (R) 186/1844

# Case 3

- 46 M
- Known CP
- Presented with Abdominal pain and vomiting
- CT-scan – Large pseudocyst
- Referred for EUS + FNA



ID:  
NAME:

DOB:

AGE: SEX: 01/06/2023 15:30:17

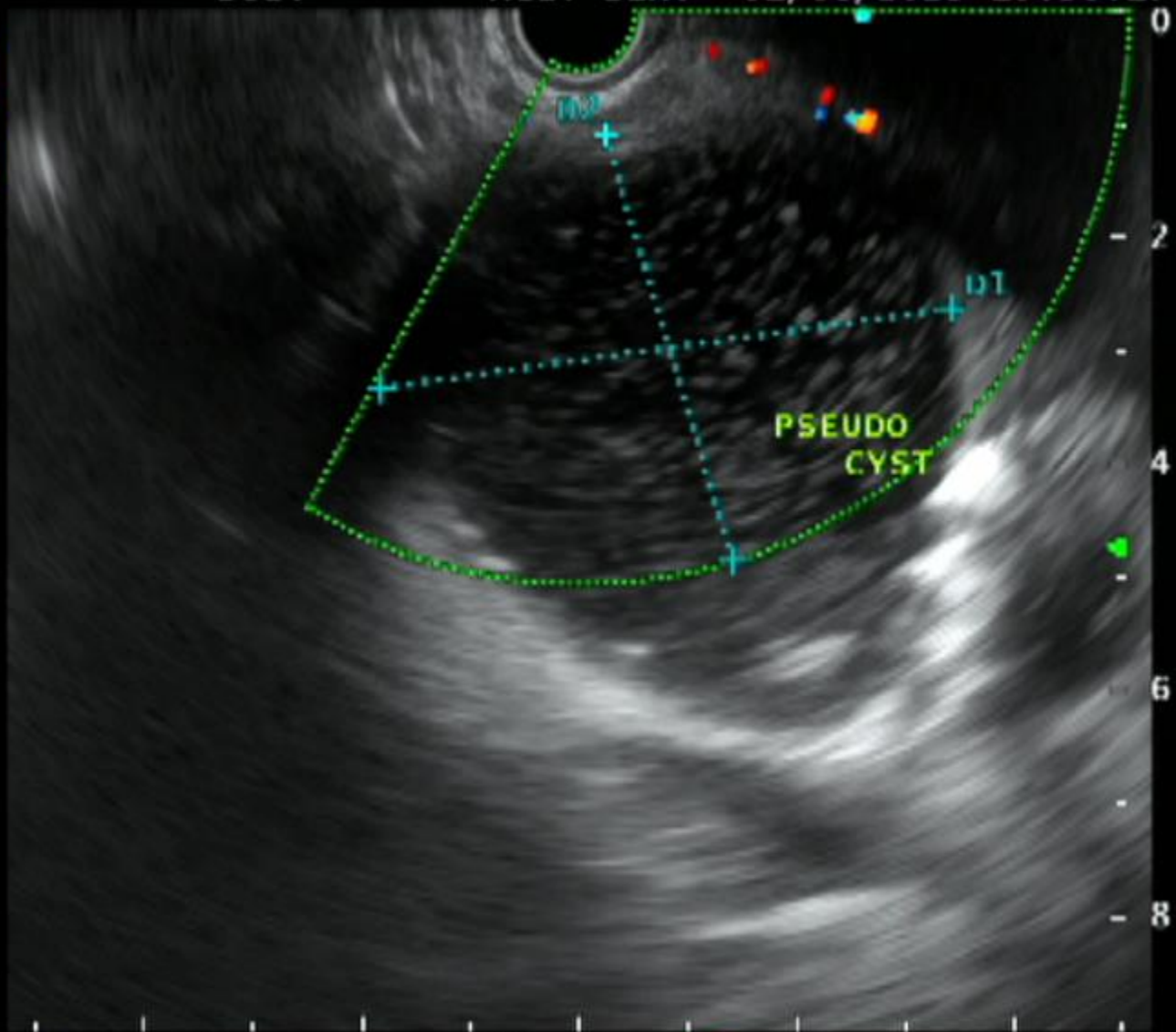
TX :100%  
MI :0.6  
TIS:<0.4



5MHz

G :14  
C : 4  
FG:18

D1: 53.1mm  
D2: 39.3mm  
D3: mm



GT 9cm MEDIA

CV: 1 (R)

38/ 113

ID:  
NAME:

DOB:


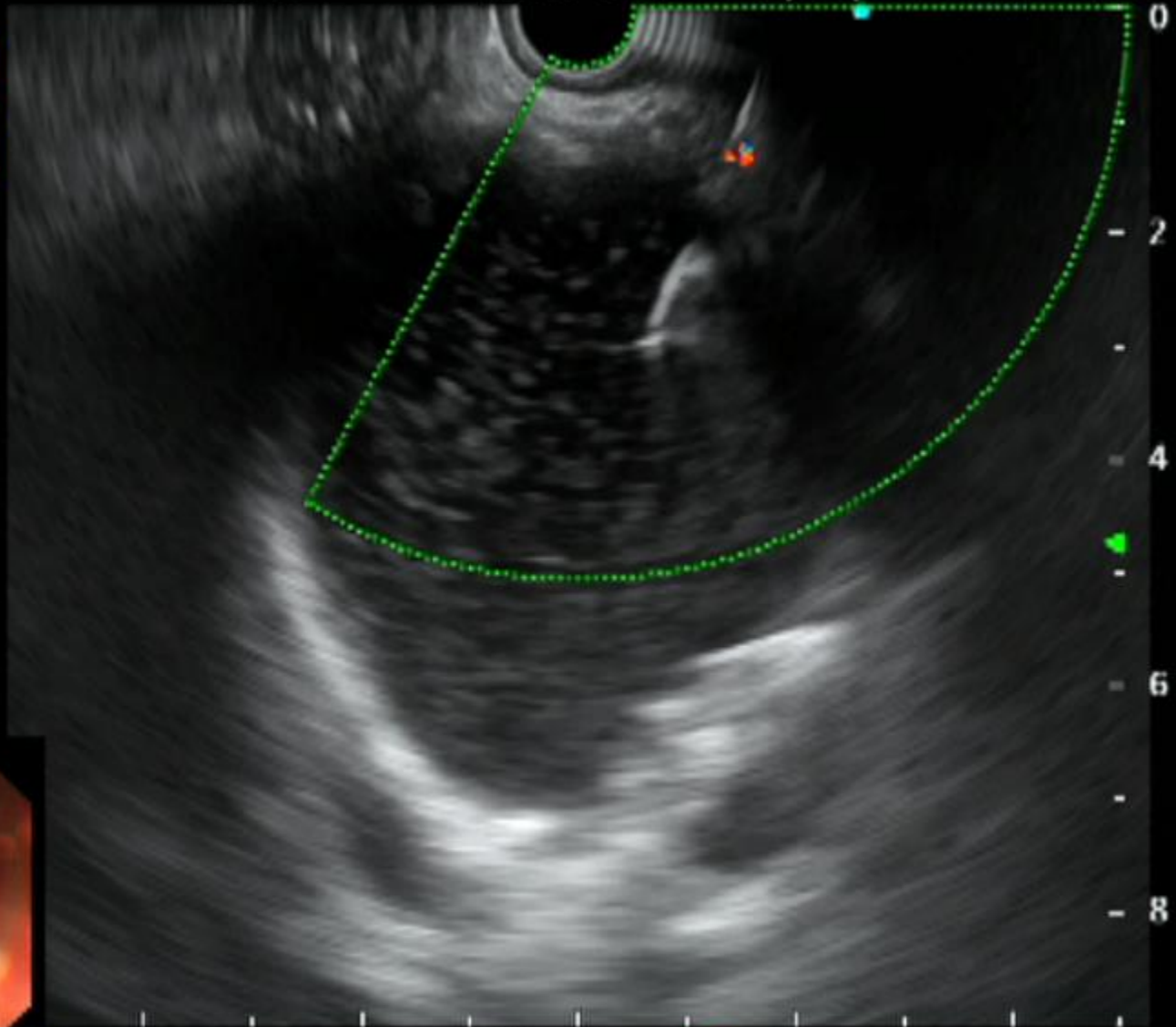
AGE: SEX: 01/06/2023 15:34:57

TX :100%  
MI :0.6  
TIS:<0.4



5MHz

G :14  
C : 4  
FG:18



CV: 1 (R)

Dr H Ahmed, BDGH

ID:

Имя:

Сек: Ам:

В.О.В.:

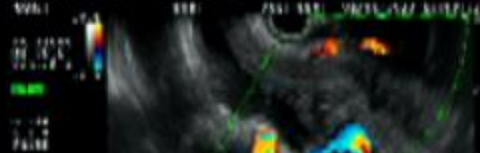
01/06/2023

15:59:33

■ ■ ■ / ---

0/1

Fr:A1 Cm:0



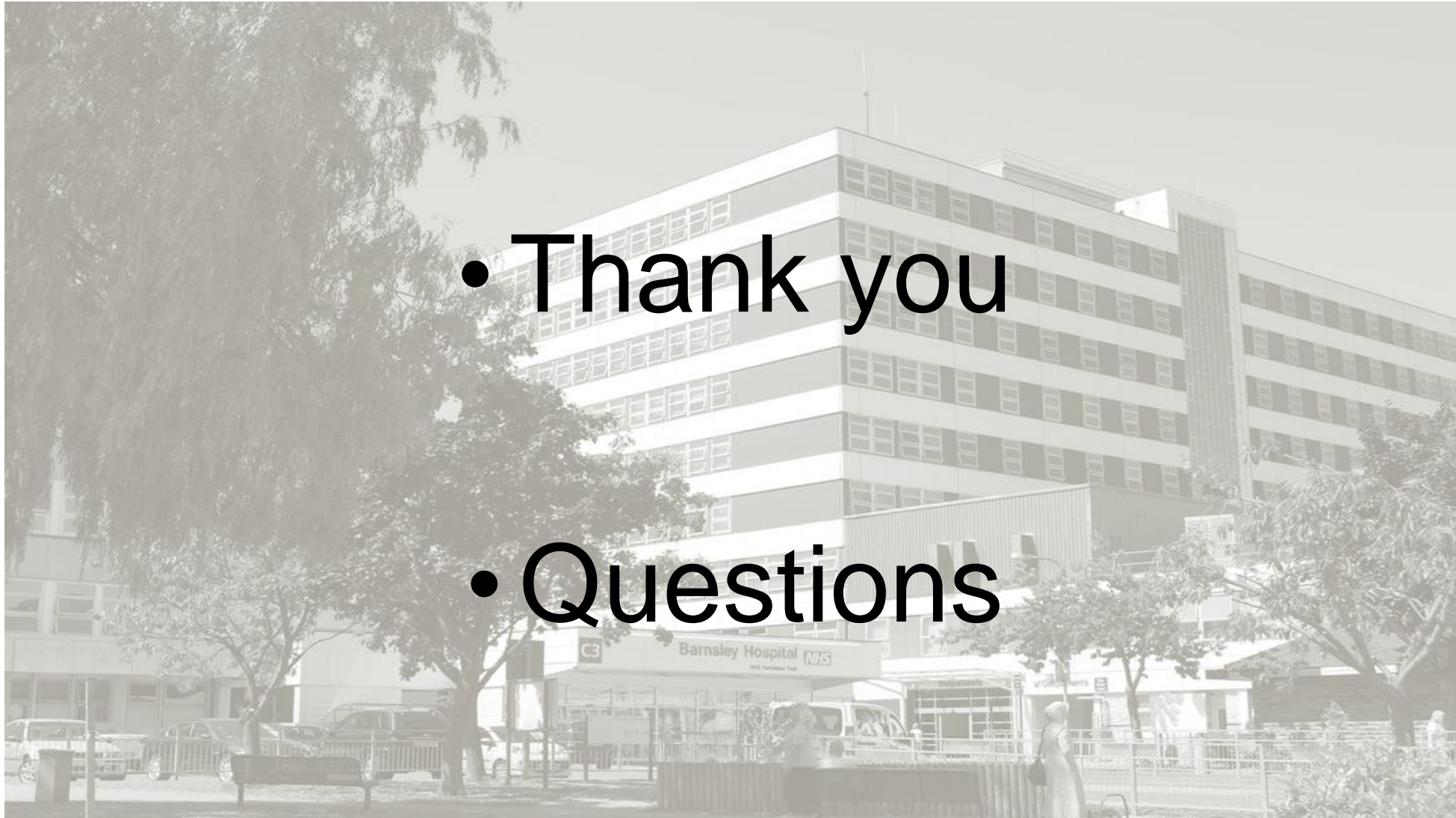Comment:

# Complications

- Sore throat
- Allergies to medication & throat spray
- Respiratory issues
- Teeth or bridgework damage
- Bleeding
- Perforation
- Pancreatitis
- Infection – specially after cyst fluid aspiration
- Incomplete procedure

# What you need to know from PC point of view

- Most of referral are from MDT & Gastroenterologist
- Dilated bile ducts with contraindications for MRI



- Thank you
- Questions

Dr H Ahmed, BDGH