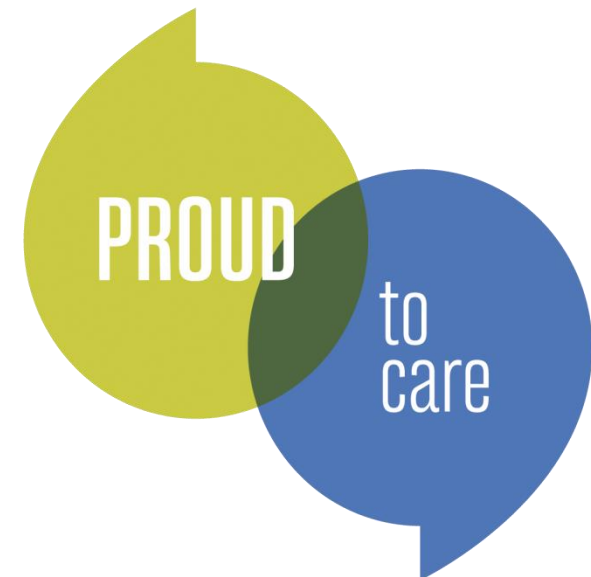

Characteristics of Neck Lumps in support of the Primary Care Neck Lump Pathway

Presenter Name: Martin Wickham

Presentation Date: 19/01/2022





Why Discuss Neck Lump Characteristics?

You might be thinking:

“What is the point in learning more about neck lump characteristics.....”



Why Discuss Neck Lump Characteristics?

I think the answer is.....



Why Discuss Neck Lump Characteristics?

Furthermore, please remember that using this pathway is not disadvantaging the patient.....



Why Discuss Neck Lump Characteristics?

And by reducing the number of patients initially being referred on the 2 Week Wait (2WW) pathway the journey of those patients who genuinely should be on the 2WW pathway is greatly improved.



Why Discuss Neck Lump Characteristics?

I appreciate that so far I have simply reiterated some of what Lisa and Gill have been saying.....



Neck Lump Characteristics

Ok 6 slides in and I haven't even got to the point yet!

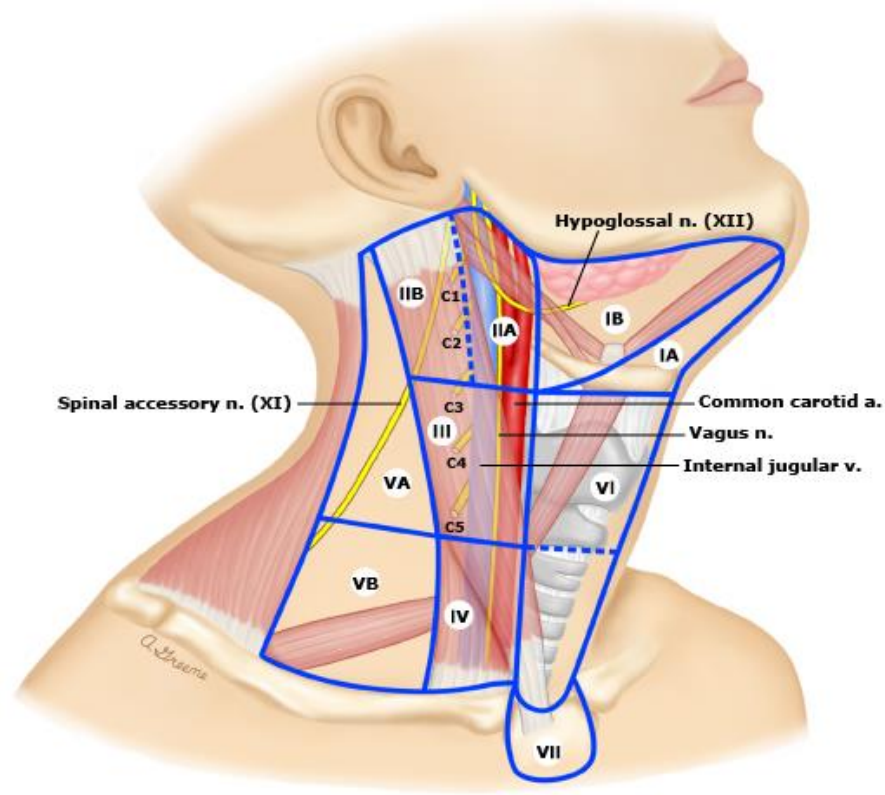
Neck Lump Characteristics

- In essence the lateral neck is divided into anterior and posterior triangles bilaterally. The posterior border of sternocleidomastoid (SCM) muscle separates the 2 triangles.
- The area anterior to posterior border of SCM is anterior triangle, the area posterior to posterior border of SCM is posterior triangle.

Neck Lump Characteristics

- The anterior triangle is divided into thirds, upper (mandible to hyoid), middle (hyoid to cricoid) and lower (cricoid to clavicle).
- In between the right & left lateral necks and below hyoid level is the central compartment.

Neck Lump Characteristics



Neck Lump Characteristics

The following are some basic characteristics of neck lumps:

- The normal neck is very lumpy!
 - Hyoid bone
 - Laryngeal framework including Adam's apple
 - Cricoid
 - Carotid bodies
 - Transverse processes of cervical vertebrae
 - Trachea

Neck Lump Characteristics

Basic characteristics of neck lumps, continued:

- Small or large
- Single or multiple
- Soft, hard, cystic, pulsatile
- Unilateral or bilateral
- Mobile or fixed
- Superficial or deep
- Slowly or rapidly growing



Neck Lump Characteristics

Characteristics of Benign Lump:

- Small
- Single
- Soft
- Mobile
- Superficial
- Unilateral

Neck Lump Characteristics

Characteristics of Malignant Lump:

- Large
- Multiple
- Hard
- Fixed
- Deep
- Bilateral

Neck Lump Characteristics

Lymph node(s) >1 cm, firm to hard, in upper and/or middle thirds of anterior triangle of neck are likely to be malignant (metastatic from a H&N primary eg tonsil, tongue base).



Neck Lump Characteristics

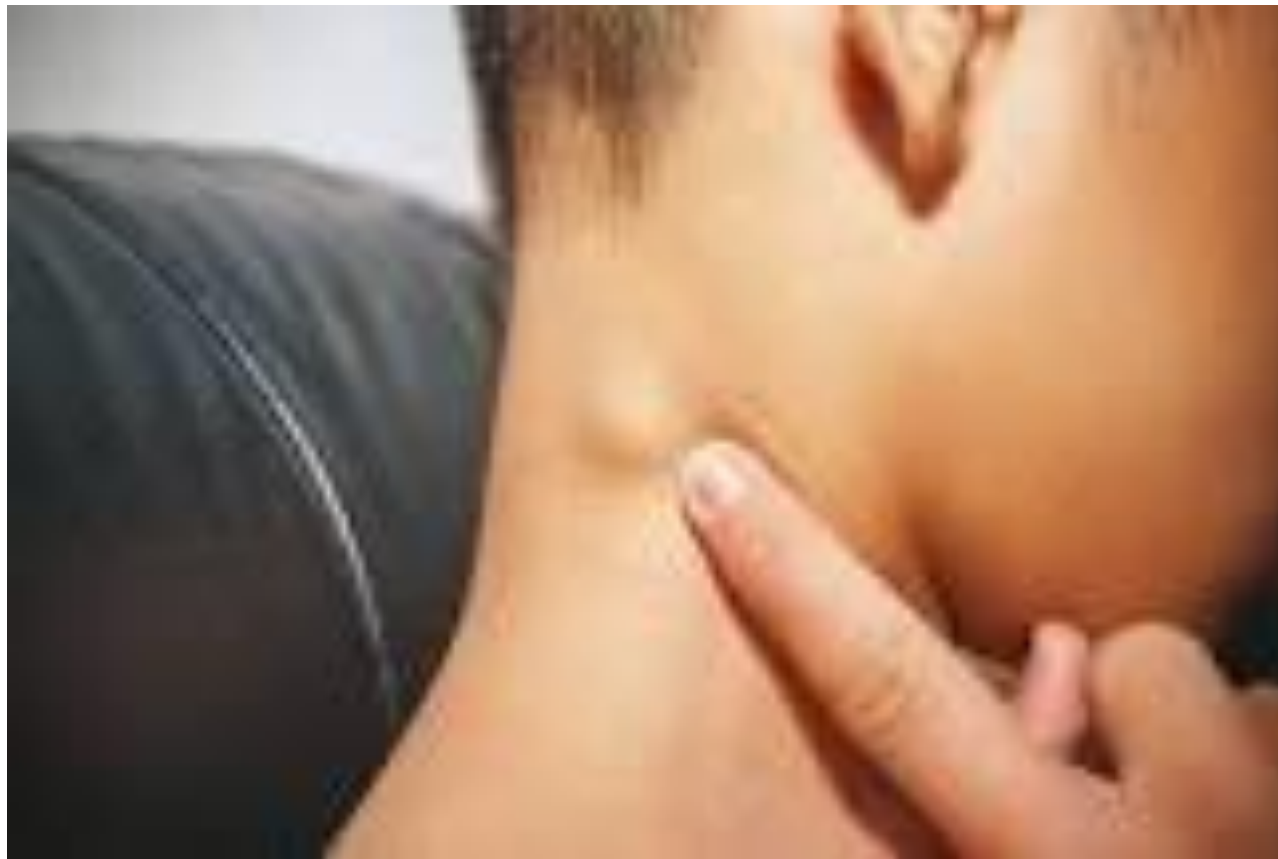Lumps in medial aspect of lower third of anterior triangle are likely to arise from thyroid, the vast majority of which will be benign.



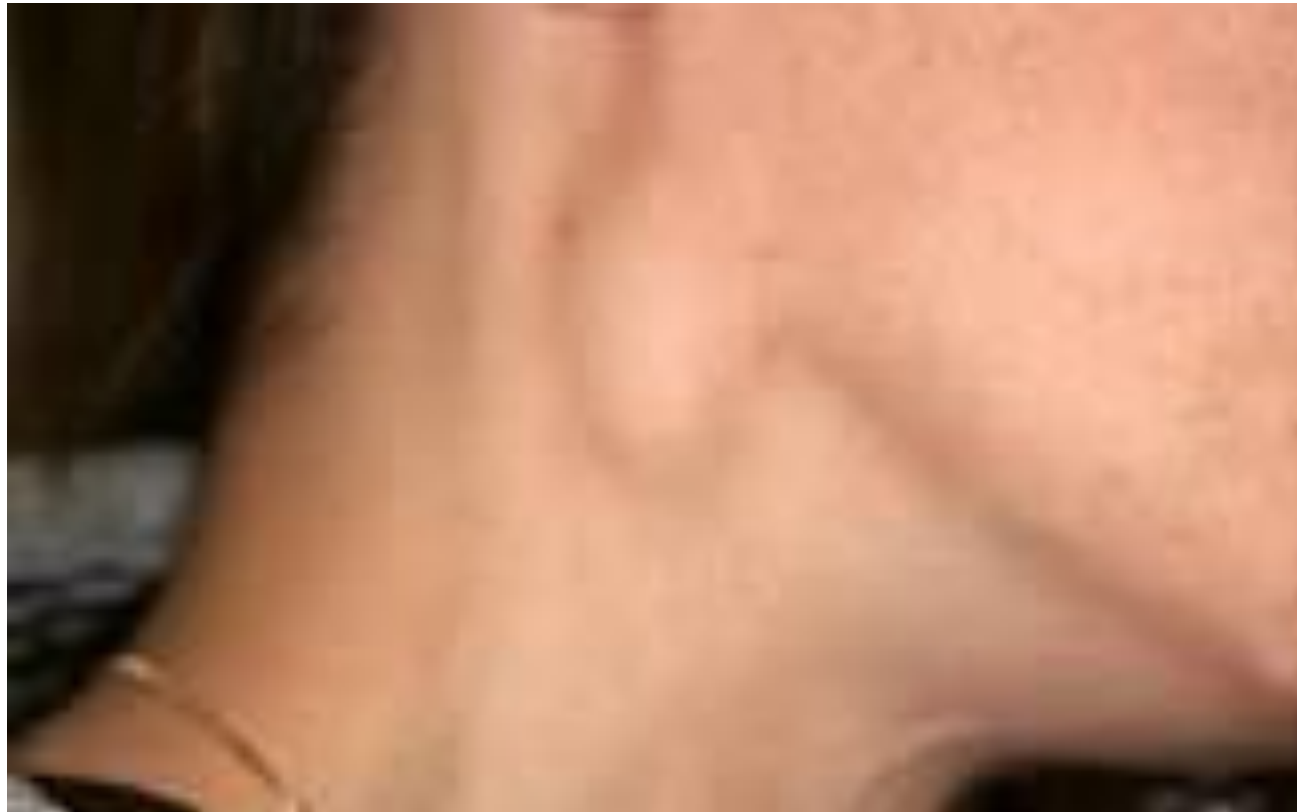Neck Lump Characteristics

Lumps in lateral aspect of lower third of anterior triangle may be metastatic from primaries below clavicle.

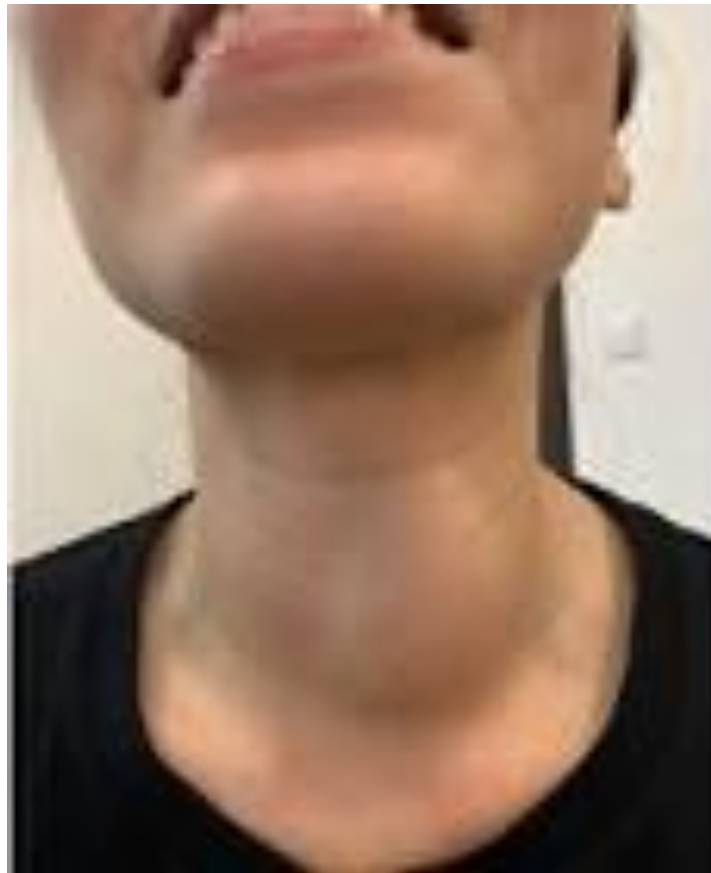Neck Lump Characteristics



Neck Lump Characteristics



Neck Lump Characteristics





Neck Lump Characteristics

The bottom line is when you are faced with an adult patient with a neck lump other than a superficial skin lesion, and with no other symptoms, please refer them via the Primary Care Neck Lump Pathway.

Thank you!

Any Questions?

