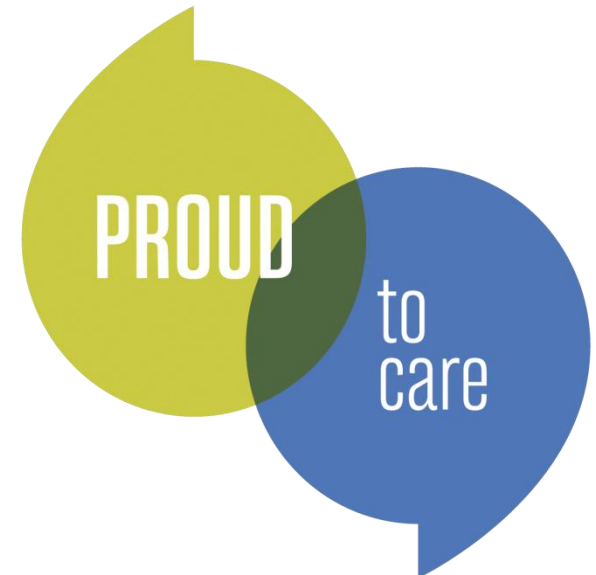

The Stiff shoulder

Margo Dirckx

BEST event 2023



> 60

- ? Clinical tests
- ? Investigations
- ? Differential diagnosis

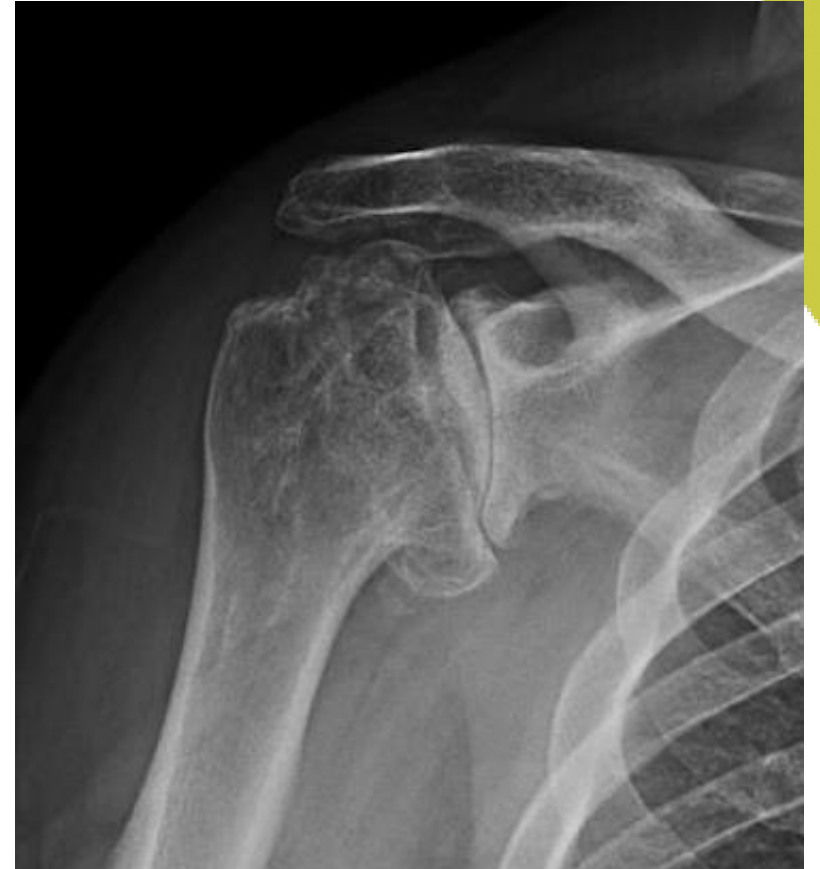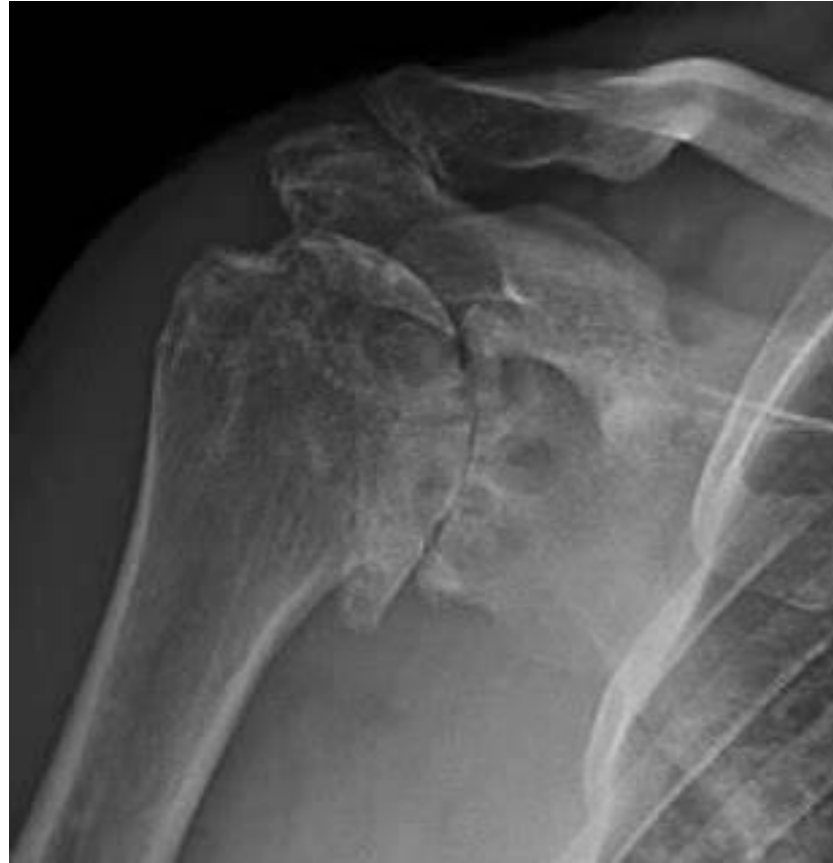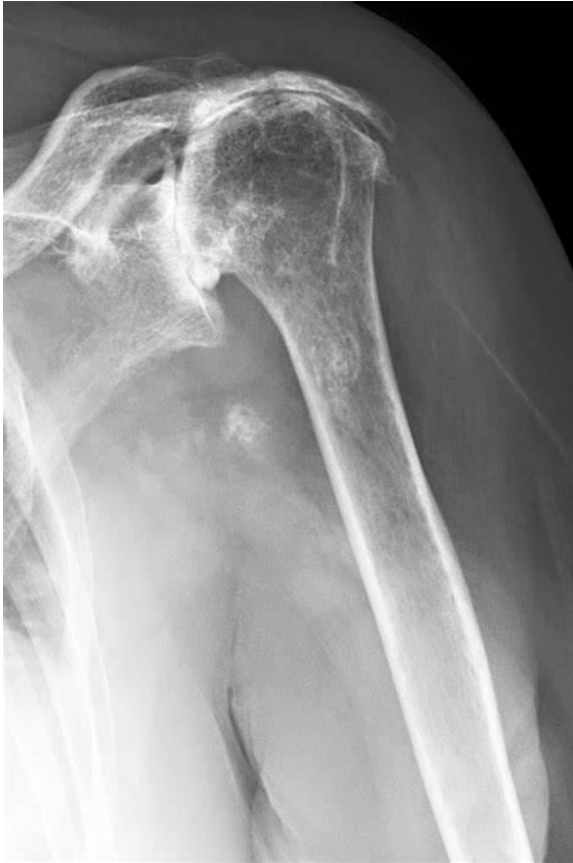Clinical examination

- Active range of motion
- **PASSIVE** Range of motion
- Crepitus

~~Ultrasound~~

- “full thickness tear of the supraspinatus and infraspinatus. Fluid in the bicipital sheath”

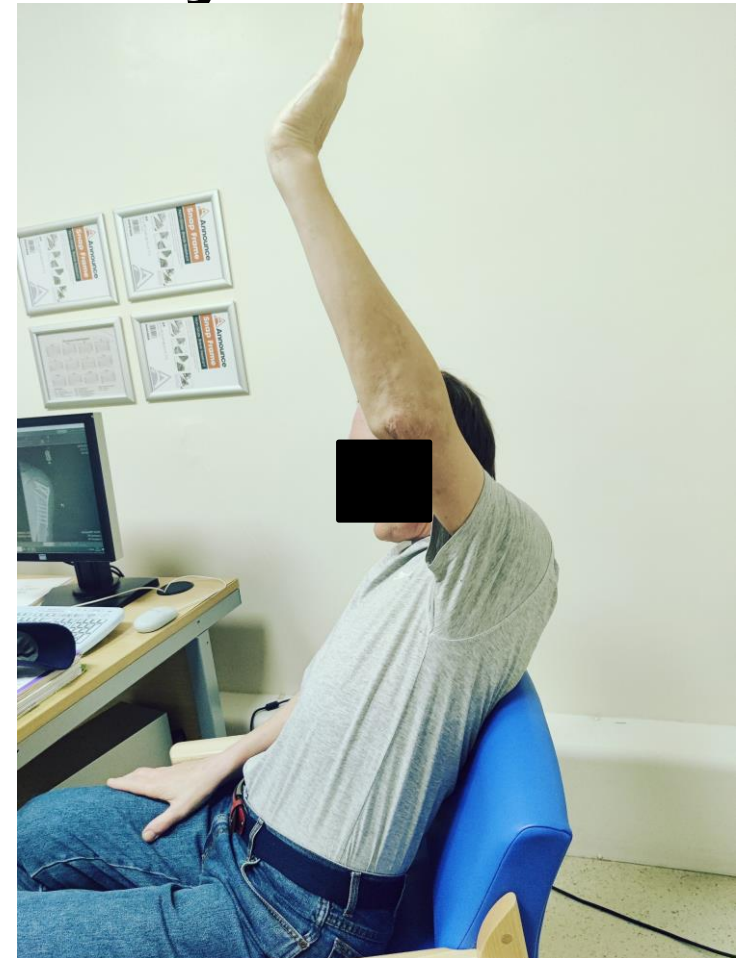
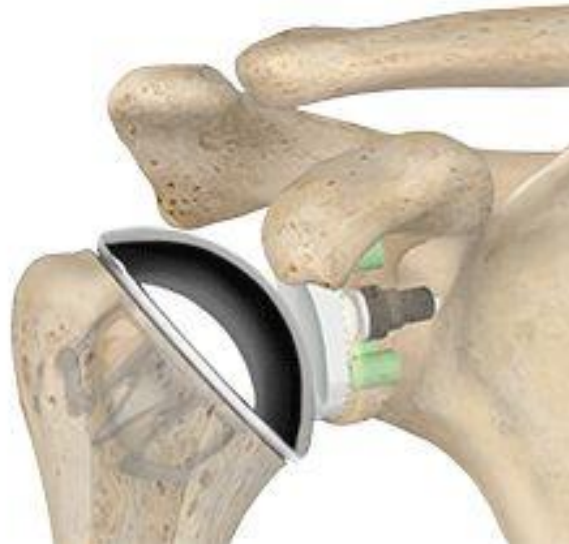
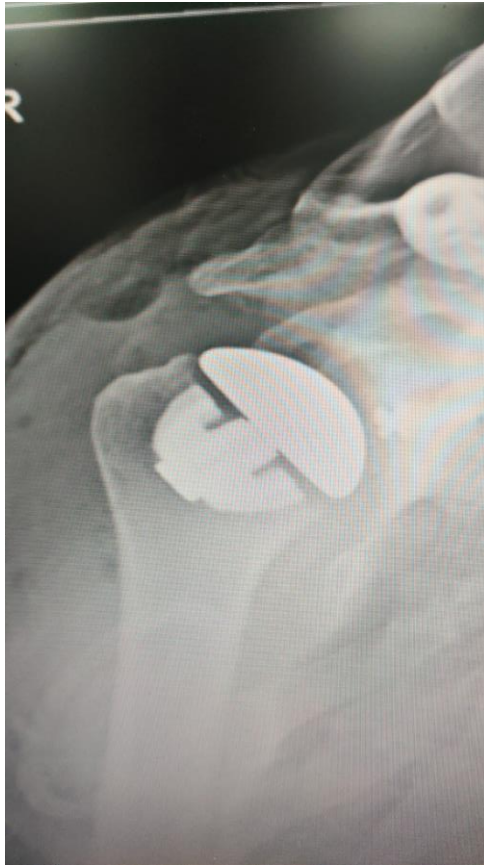X-ray



Shoulder osteo-arthritis Treatment

- Analgesia
- Physio
- ? IA injections
- → Surgery

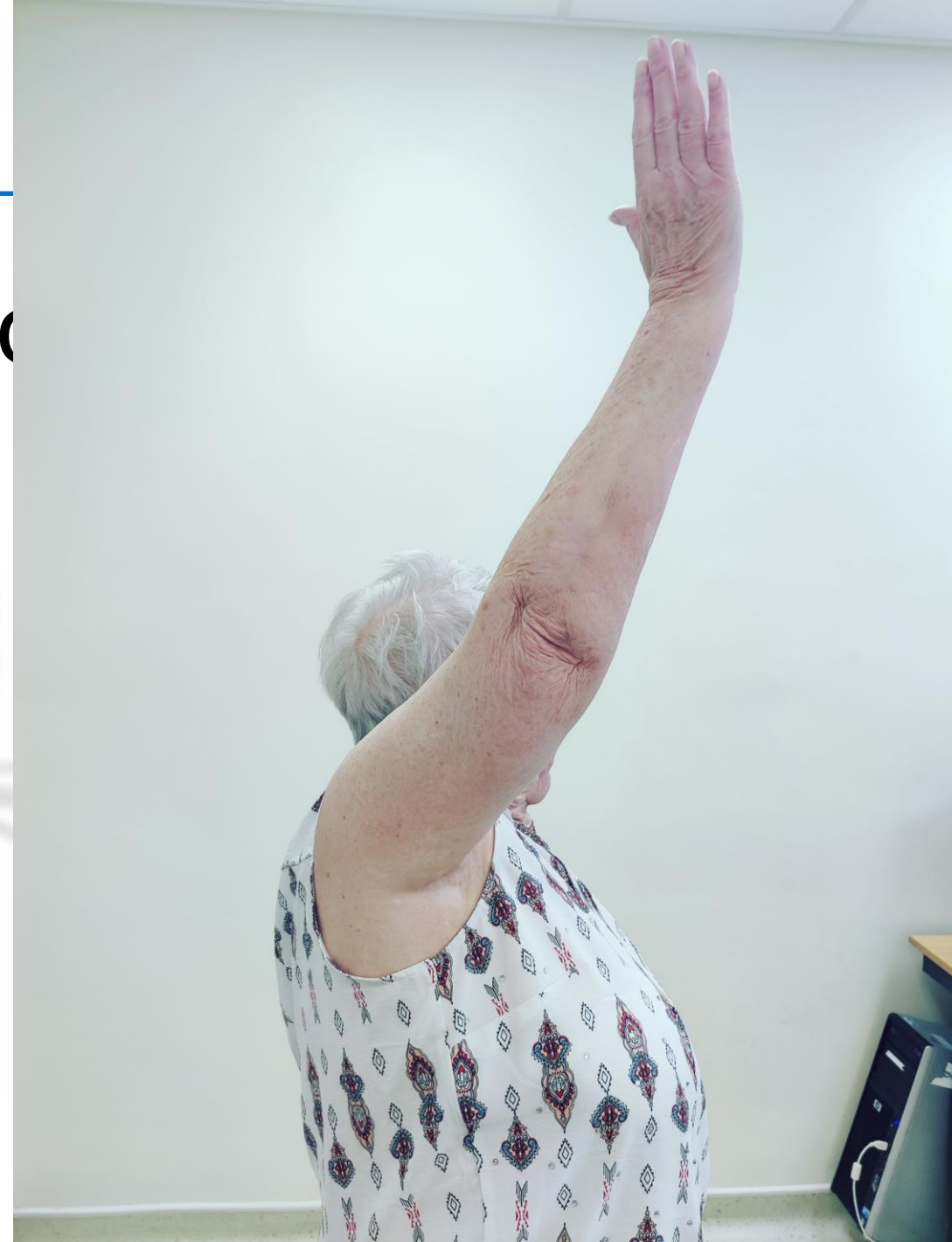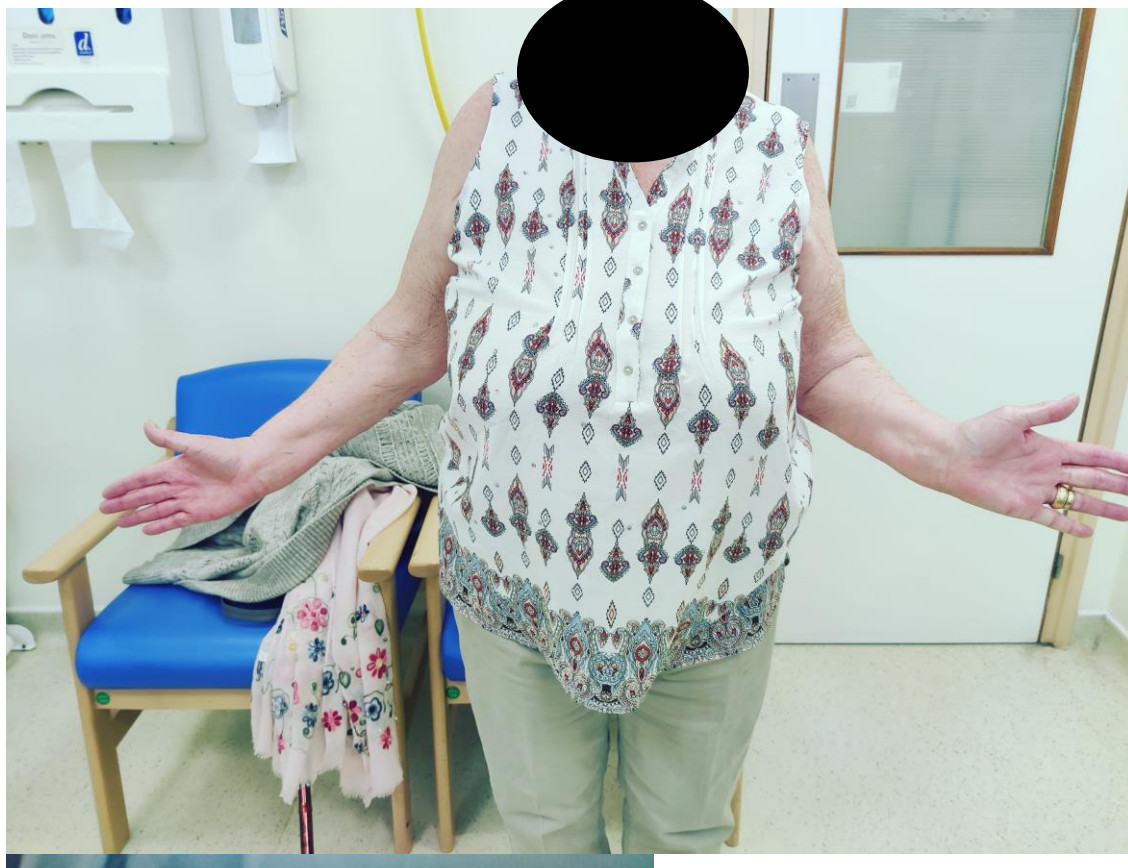“Anatomic” Shoulder arthroplasty



PROUD

to
care

“Reverse” Shoulder arthro

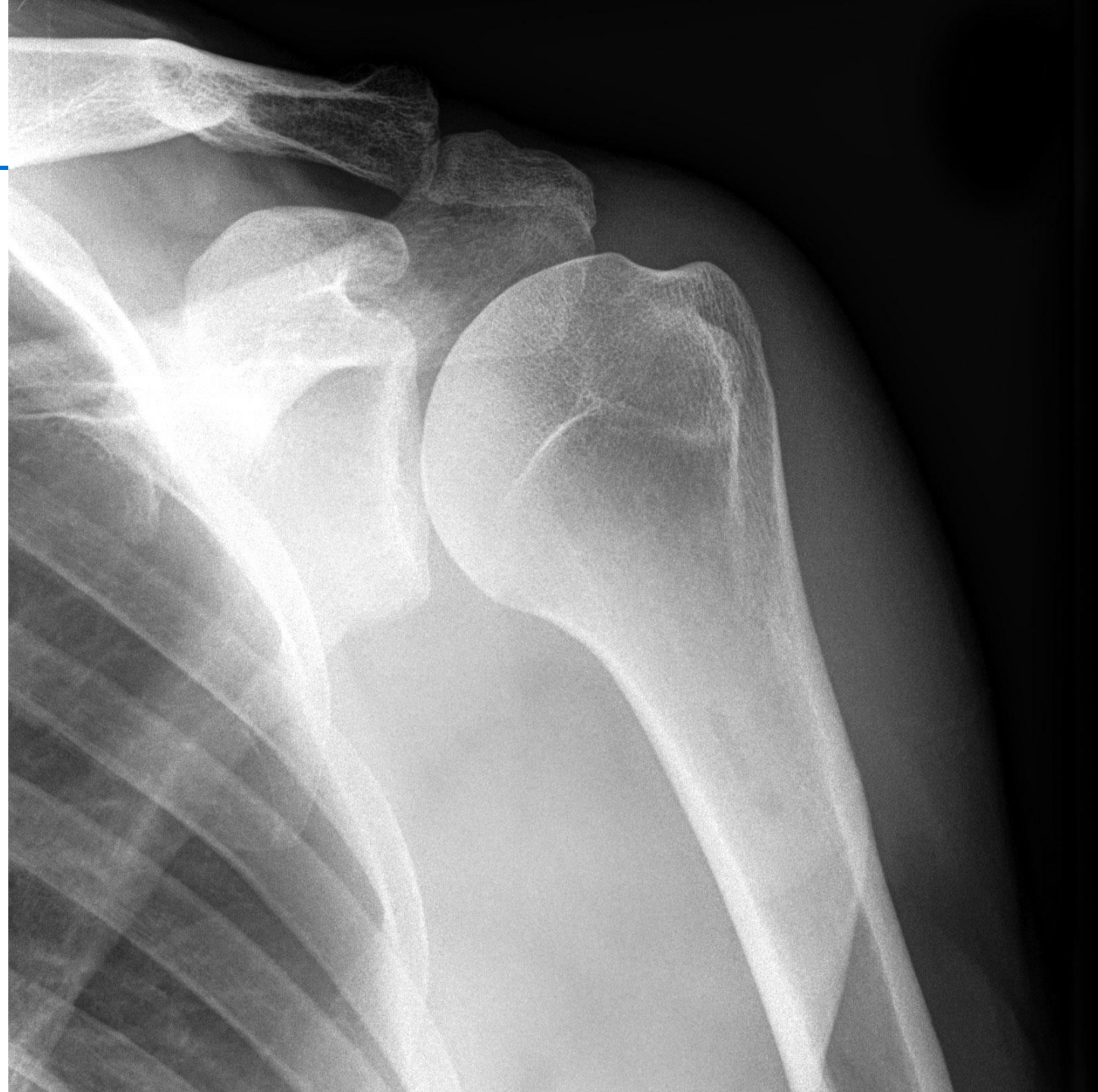



40 – 60 y old

- ? Clinical tests
- ? Investigations
- ? Differential diagnosis

PROUD
to
care



Barnsley Hospital
NHS Foundation Trust



Ultrasound

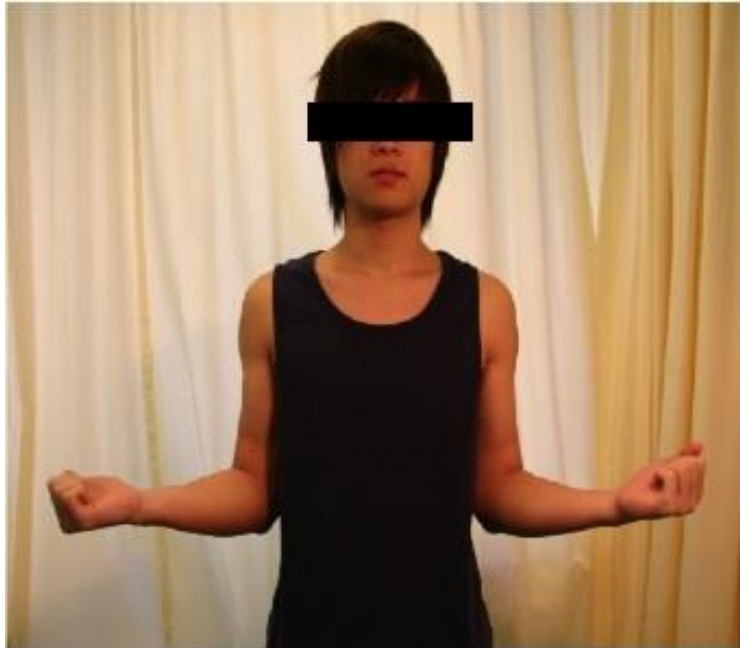- “intact rotator cuff. Effusion around the long head of biceps. Fluid in subacromial space indicative of bursitis”

MRI

- “intact rotator cuff. Effusion around the long head of biceps. Fluid in subacromial space indicative of bursitis”

- Pain out of proportion
- No history of trauma
- Night pain ++
- Physio: “ does not work, only causes pain”

!!! Passive external rotation



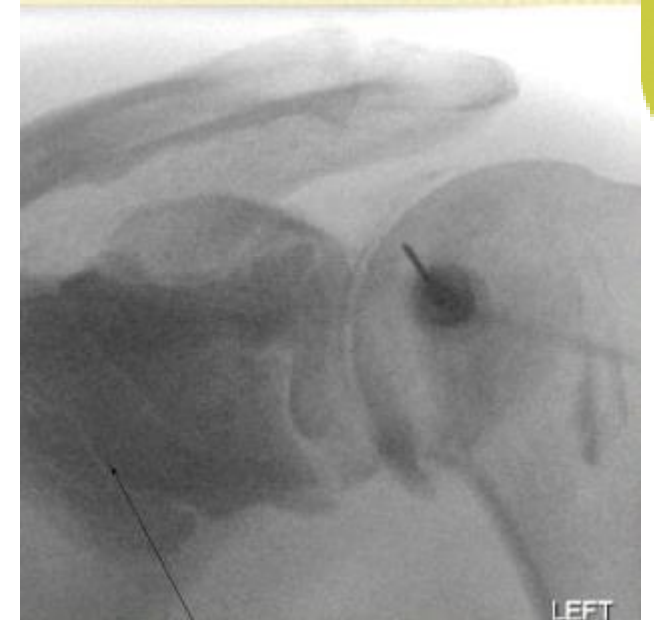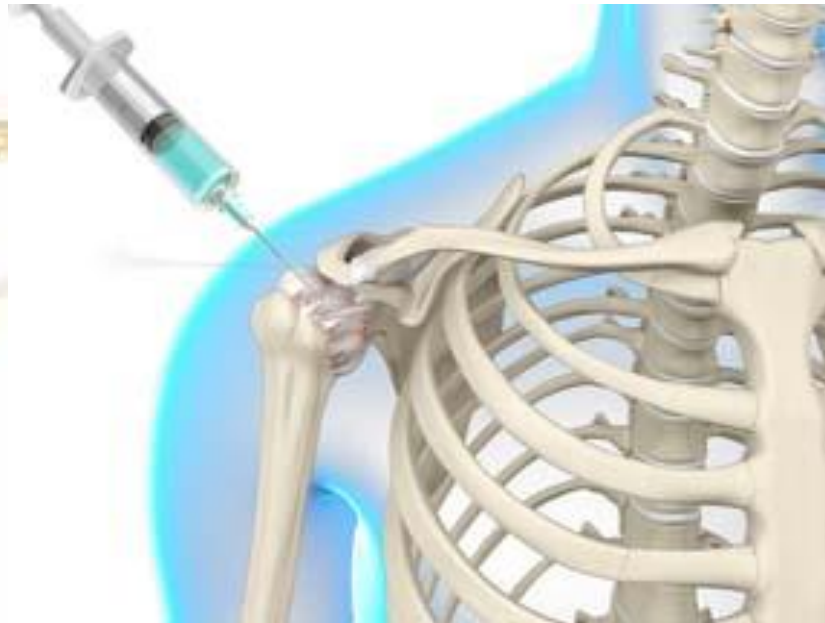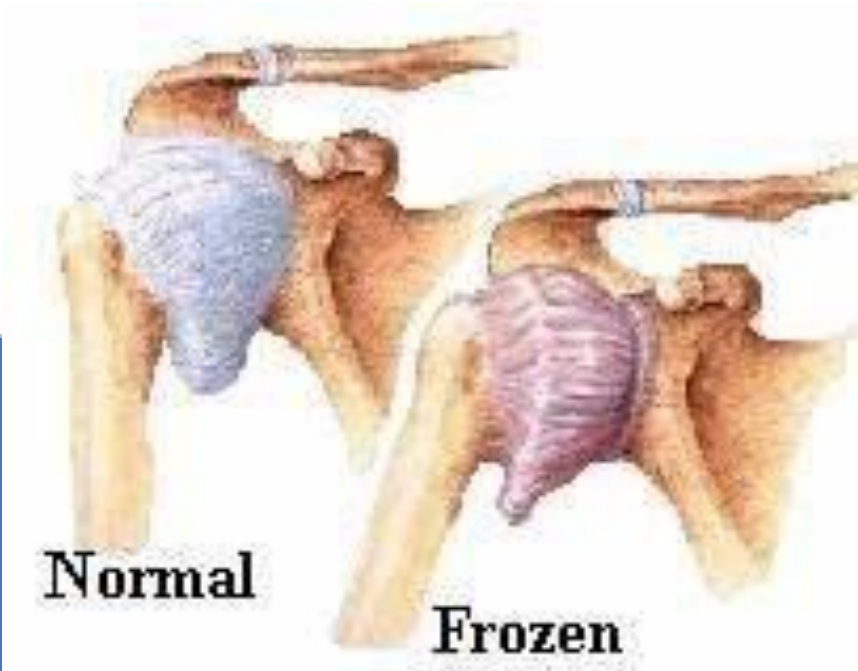“Frozen shoulder”

- = loss of PASSIVE movement
- Pain out of proportion
- ! Diabetes, pregnancy, post COVID vaccine

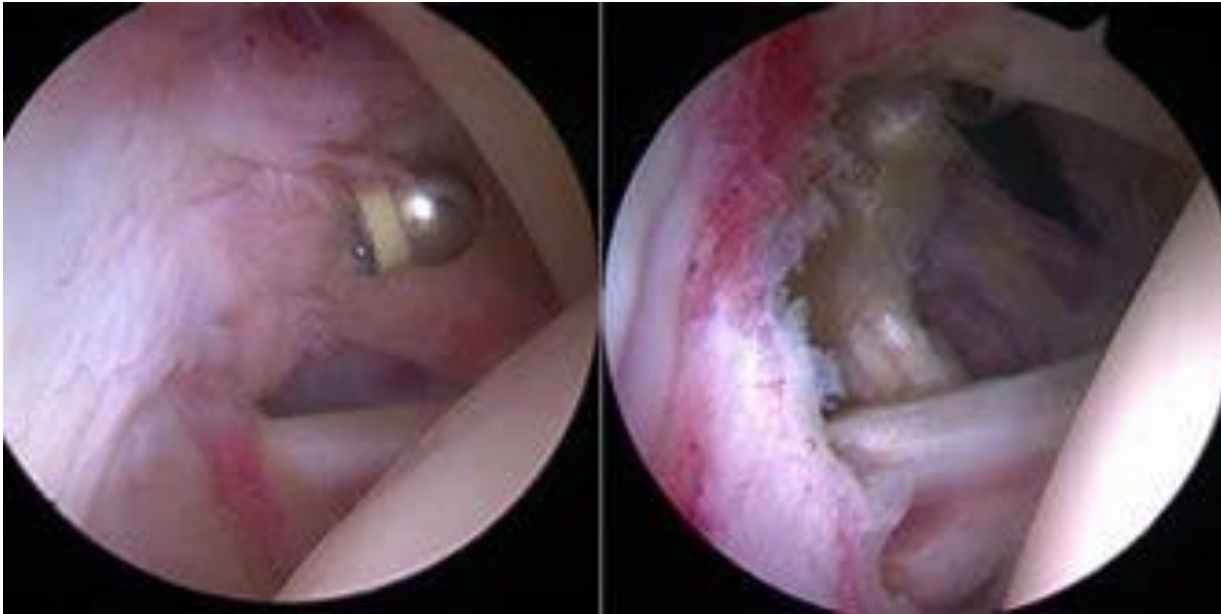Treatment

- Physio: Gentle, passive stretching, no resistance bands!
- IA injection
- Symptoms >6 weeks: refer

Hydrodilataion



Manipulation – Capsular release



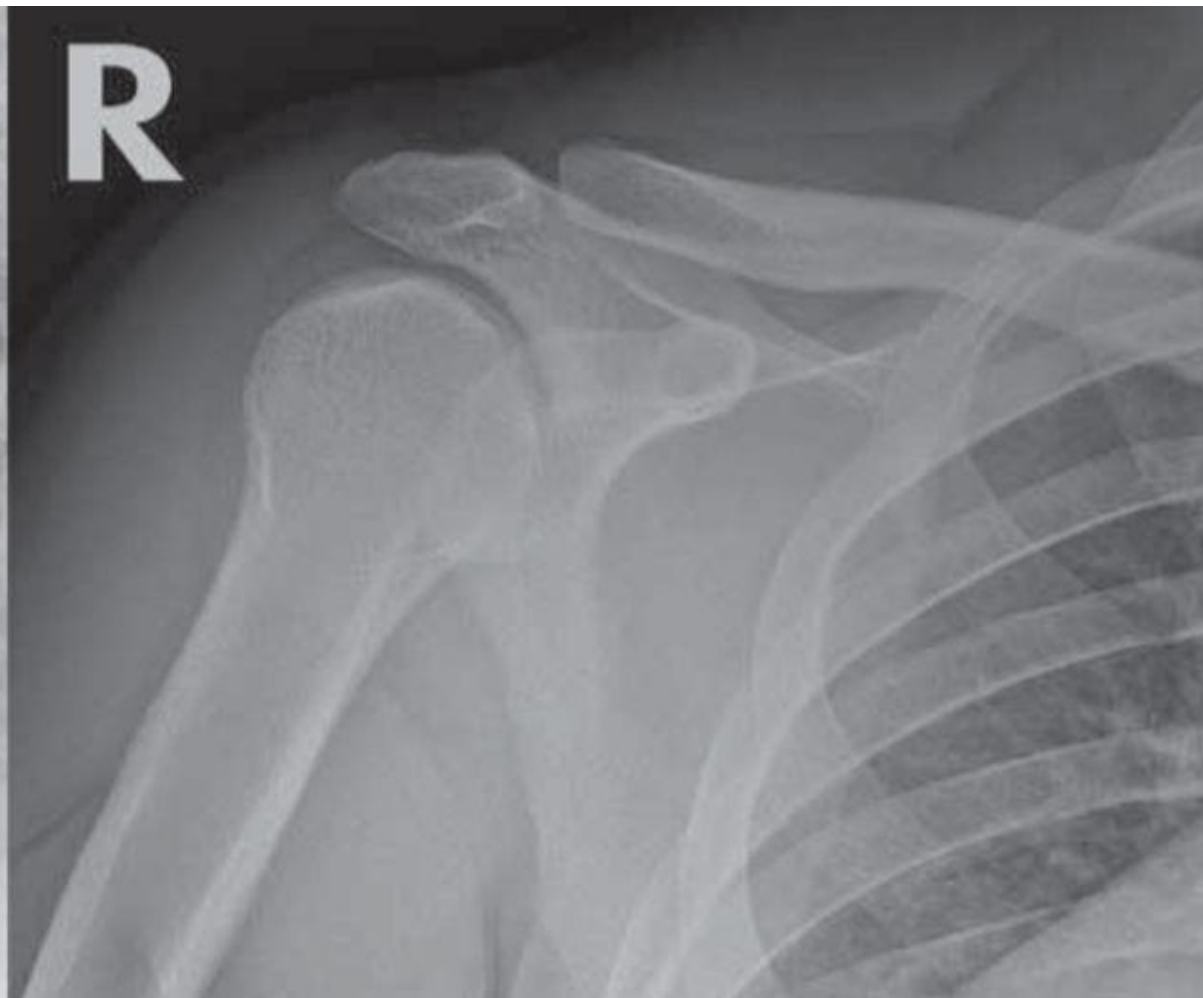
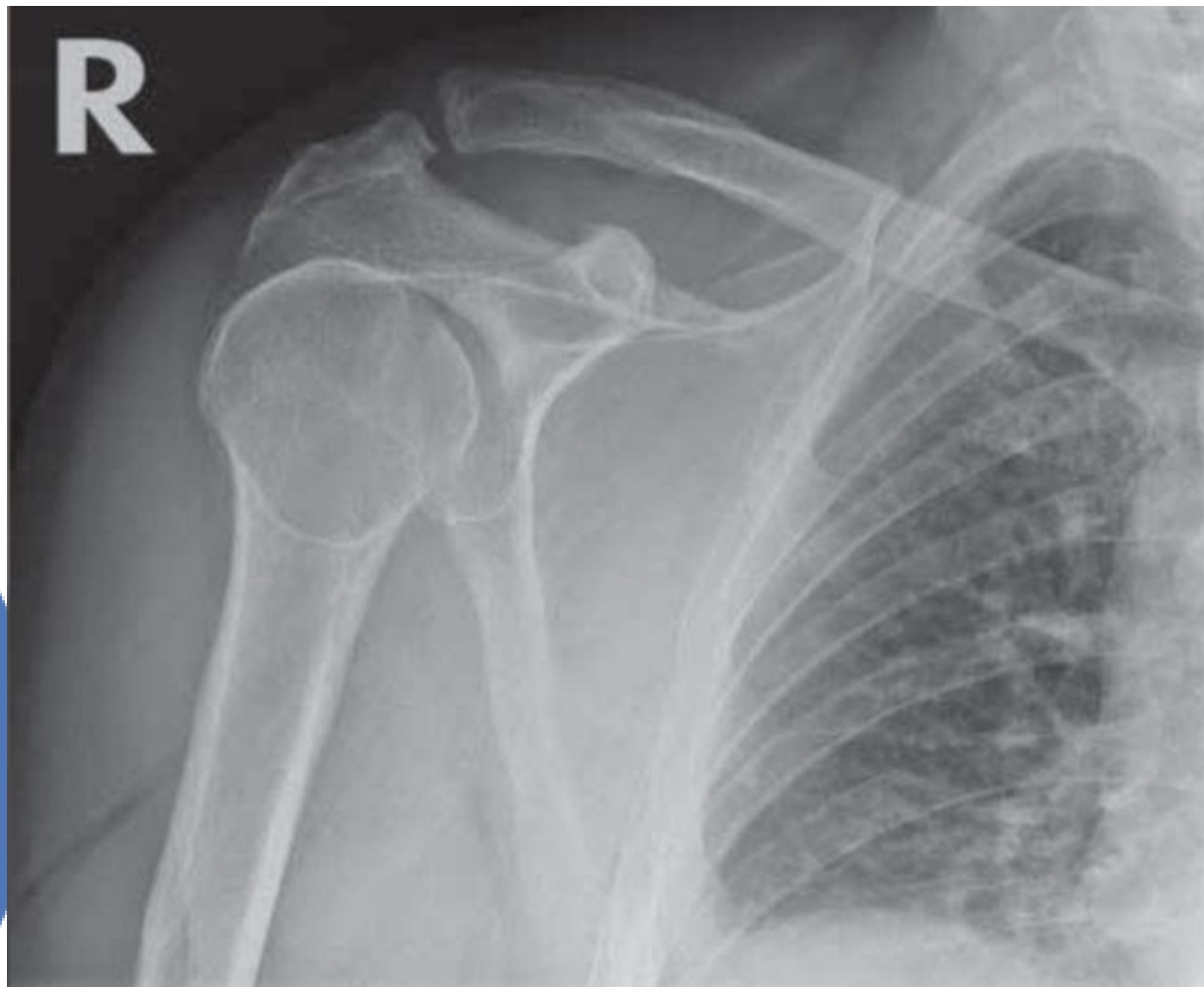


<40y, previous trauma

- ? Clinical tests
- ? Investigations
- ? Differential diagnosis

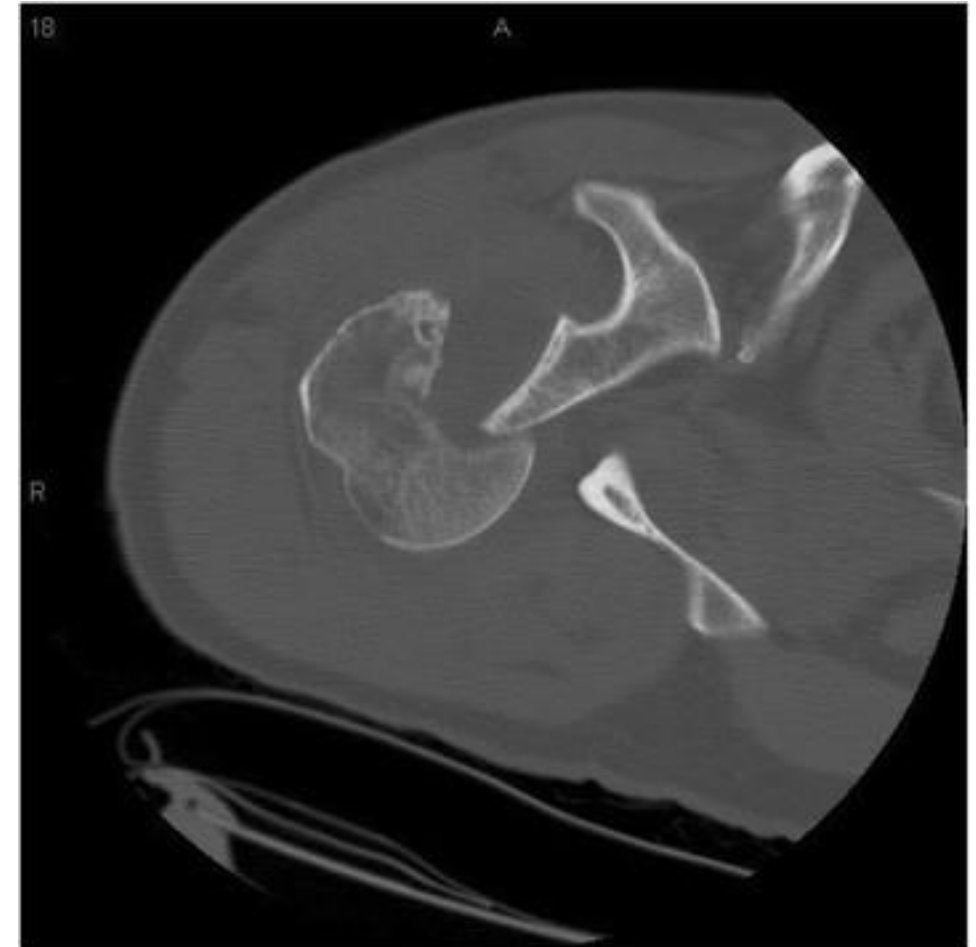
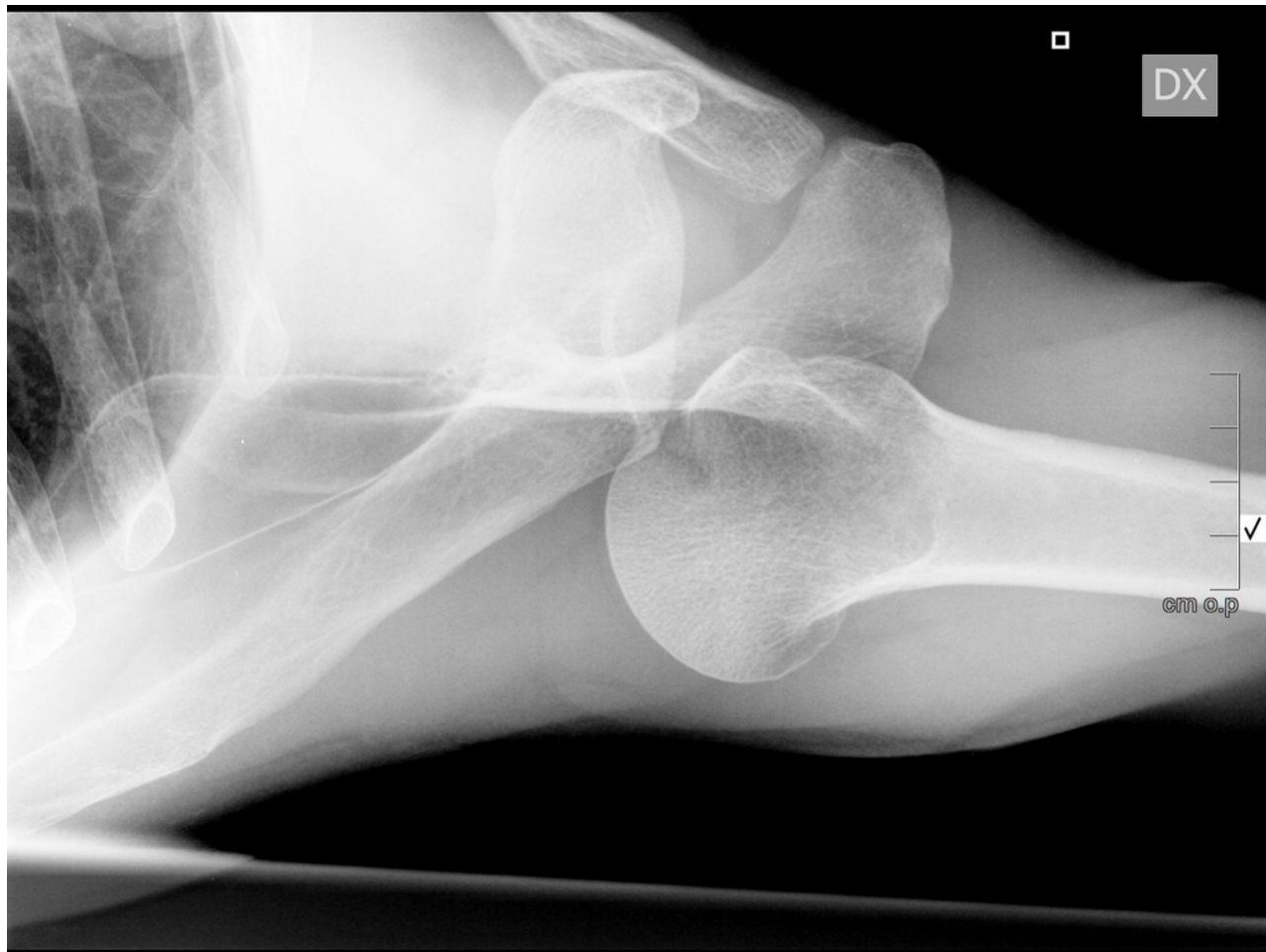Ultrasound

- “intact rotator cuff. Effusion around the long head of biceps. Fluid in subacromial space indicative of bursitis”

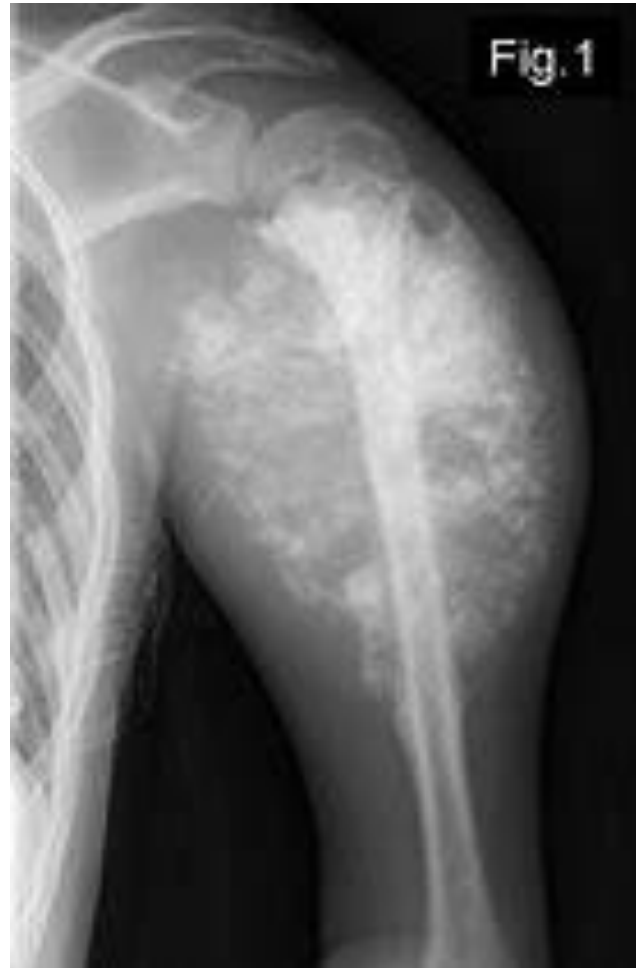



Other investigations?



<40 , no trauma



Stiff shoulder in young patient



BUT: is it truly “stiff” or mostly painful?