

Blackouts

Dr Tom Jenkins MBChB MRCP PhD

Consultant Neurologist

Barnsley, Jan 2017

Test of interactive software

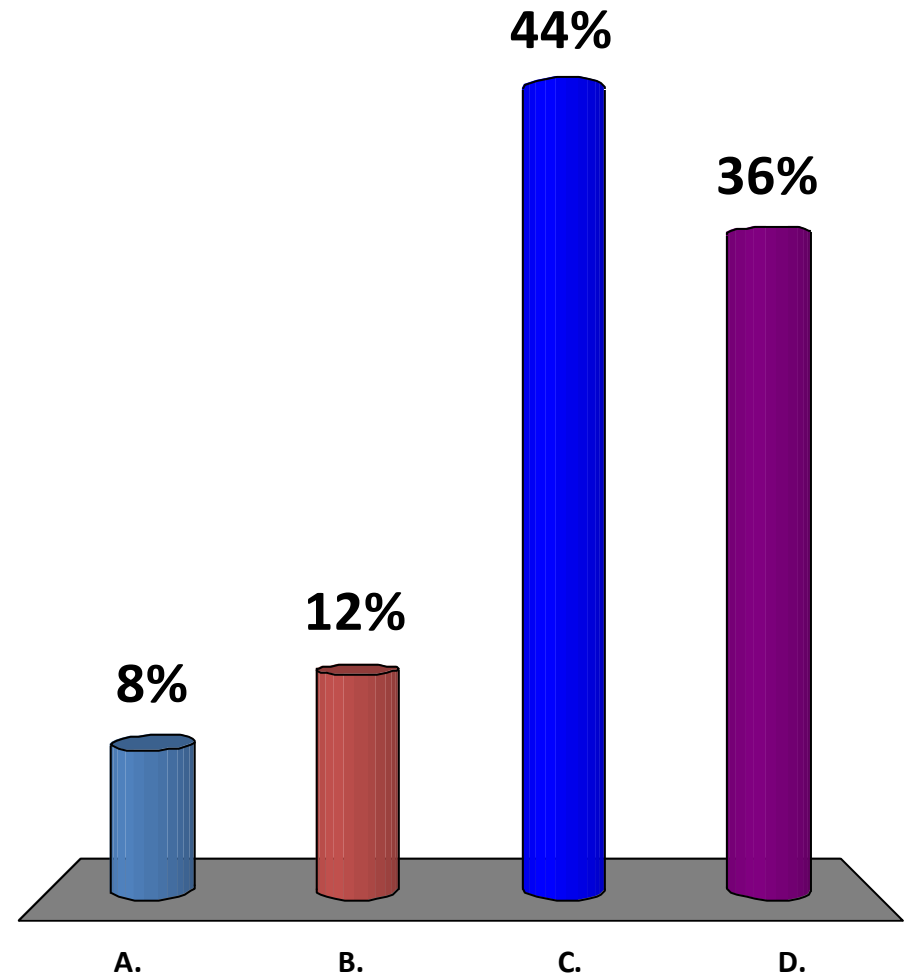
Diagnosis of blackouts is:

A. Easy

B. OK

✓ C. Difficult

D. Very difficult



Aims

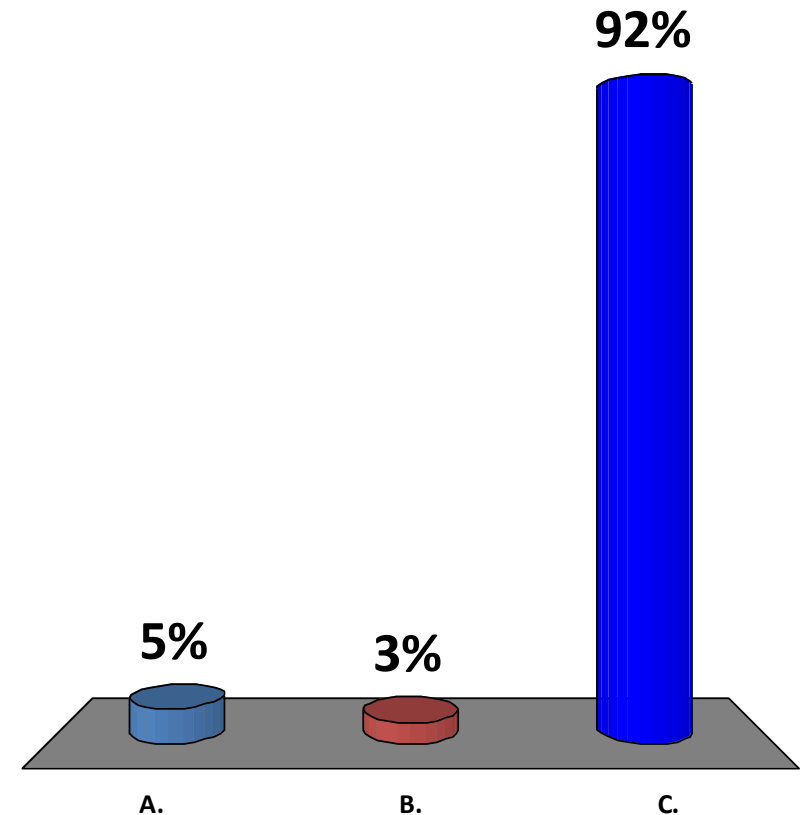
- Practical guide to diagnosis and management of blackouts
- Whom to refer to neurology
- Whom not to refer
- NICE guidelines
- Case-based diagnosis
- Videos
- Management

History

- An 18yr lady has a blackout.
- It occurred whilst standing at a bar with her friends.
- Before the event, she felt unwell, sick with her vision closing in.
- There is no FH of note.
- Her friends said she jerked for a few seconds “like a seizure”.
- She came round after a few seconds and agreed to be taken to see a doctor.
- On examination, heart sounds are normal.

What is the most appropriate course of action?

- A. Refer to neurology
- B. Refer to cardiology
- ✓ C. Perform a 12 lead ECG and if normal diagnose vasovagal syncope



NICE guideline 109 Blackouts

- Careful history
- ECG
- Refer for cardiovascular assessment: TLOC on exertion, FH, new SOB, heart failure, heart murmur, ECG abnormal
- Diagnose vasovagal syncope if no features for alternative (“brief seizure activity can occur”) AND any of 3 “P”s present: posture, provocation, prodrome

NICE guideline 109 Blackouts

- Refer for neurological assessment: tongue bite, head turn, abnormal behaviour not remembered, posturing, prolonged limb jerking, confusion afterwards, déjà vu
- Unlikely epileptic if: prodromal symptoms abolished by sitting down, sweating beforehand, prolonged standing, pallor

Whom to refer to neurology

- ?Epilepsy
- ?Non-epileptic attack disorder
- Blackout of uncertain aetiology with seizure markers

Whom not to refer to neurology

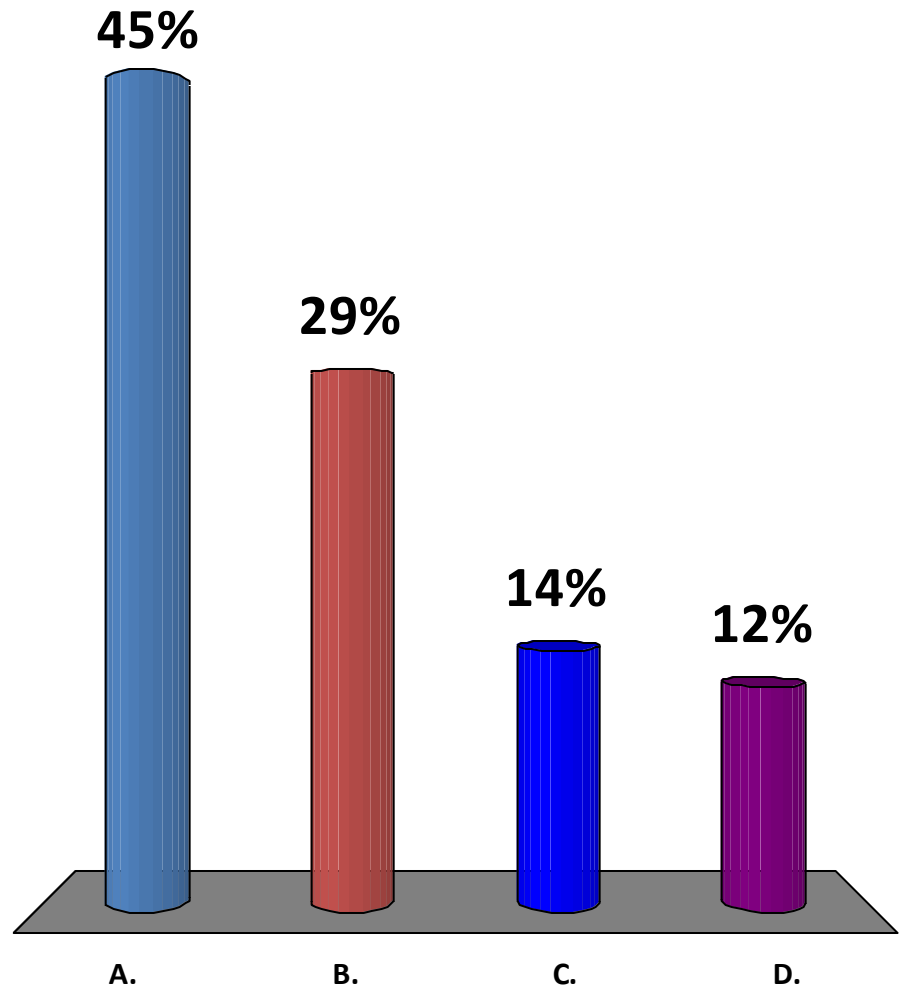
- Syncope
- Vasovagal
- “Please exclude epilepsy”

A typical blackout

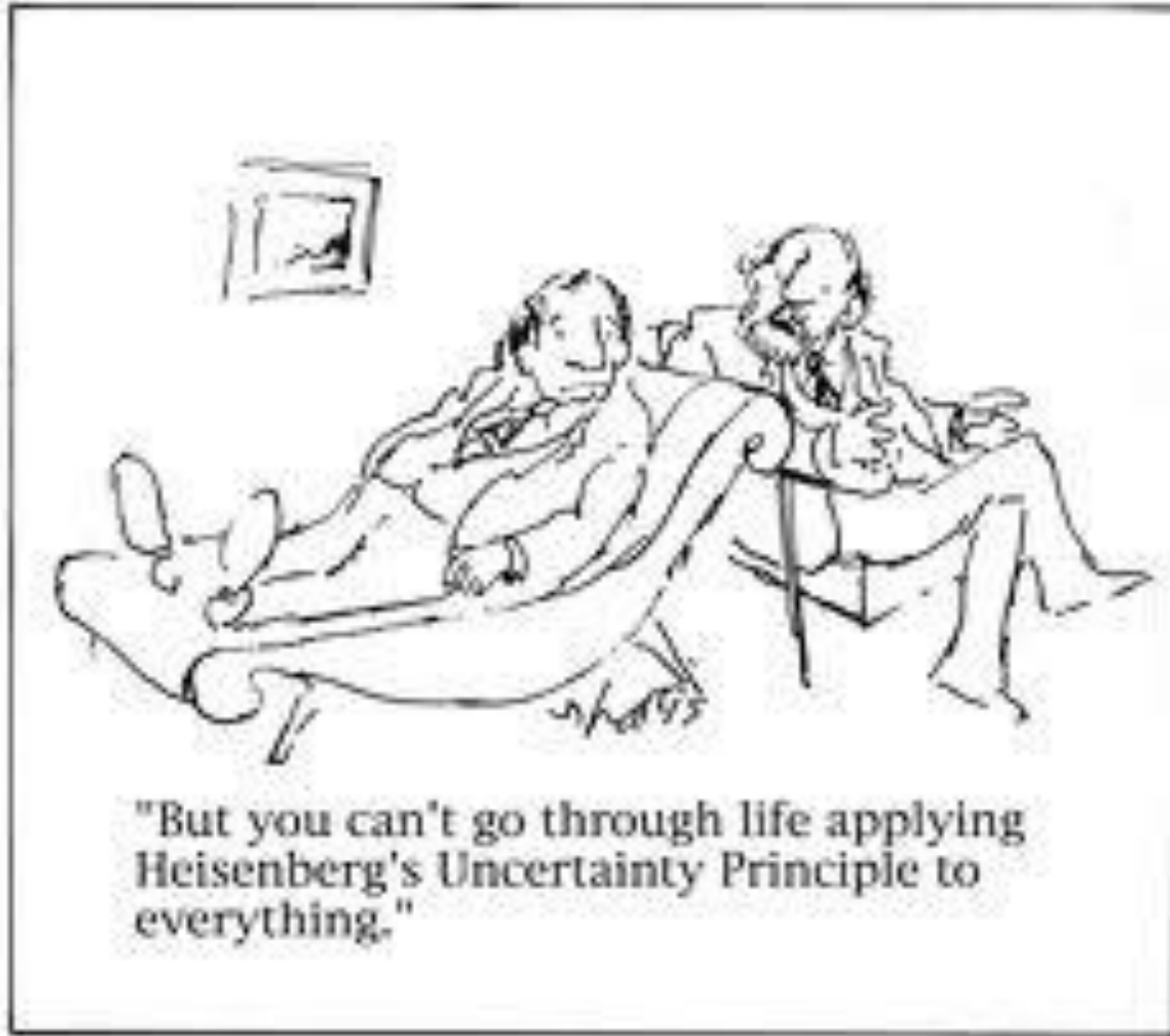- An 18 yr woman comes to see you.
- She tells you she found herself on the floor a week ago and wasn't sure how she got there.
- She says she can't remember anything about it.
- Her friend (not present) says she shook for 10 minutes.

What is the likely diagnosis?

- A. Epileptic seizure
- B. Non-epileptic attack disorder
- C. Syncope
- ✓ D. Don't know





The uncertainty principle $\Delta x \Delta p \geq \frac{\hbar}{2}$

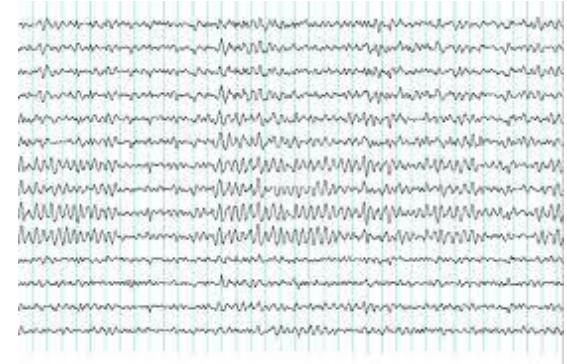


Diagnosis of epileptic seizures

- Often difficult
- Epilepsy vs NEAD vs syncope (vasovagal and cardiac)
- Rarities
- Patients recall little
- Witnesses frightened
- Mimics
- Chameleons



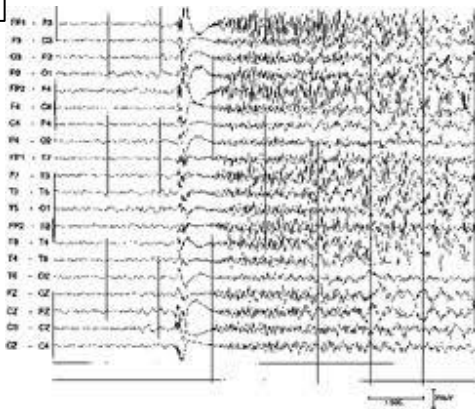Fears of misdiagnosis and overdiagnosis



Clinician error

Not diagnosing epilepsy

Not diagnosing NEAD



Potential consequence

Seizure-related mortality

Morbidity from anticonvulsants, restrictions, social stigma, missed therapeutic chance

Frequency of error


Rare

Common

Case 1

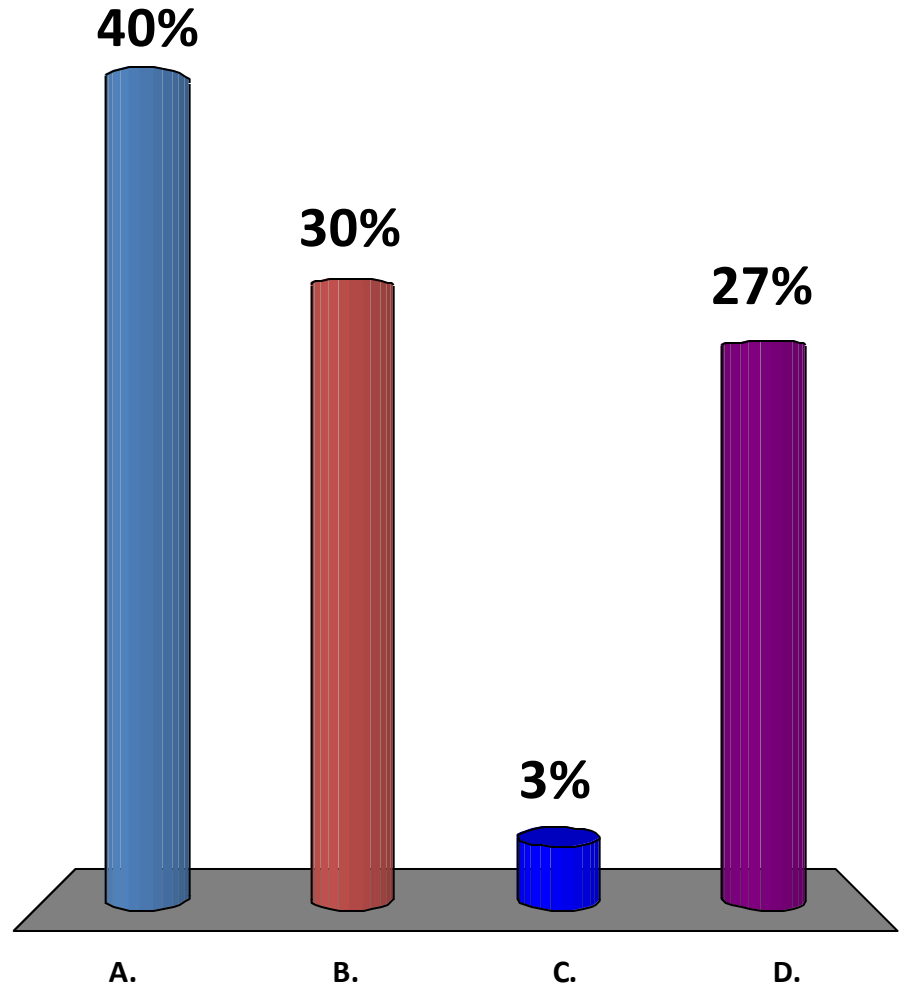
- A 30 yr man collapses in an amusement arcade.
- He recalls feeling unwell “difficult to describe” then came round on the floor of the arcade.
- He can recall little else.
- His friend came in and he was “thrashing about” for about 5 minutes, seemed confused but was back to himself after 10 minutes.

Video footage from CCTV




What is the likely diagnosis?

- ✓ A. Epileptic seizure
- B. Non-epileptic attack disorder
- C. Syncope
- D. Don't know

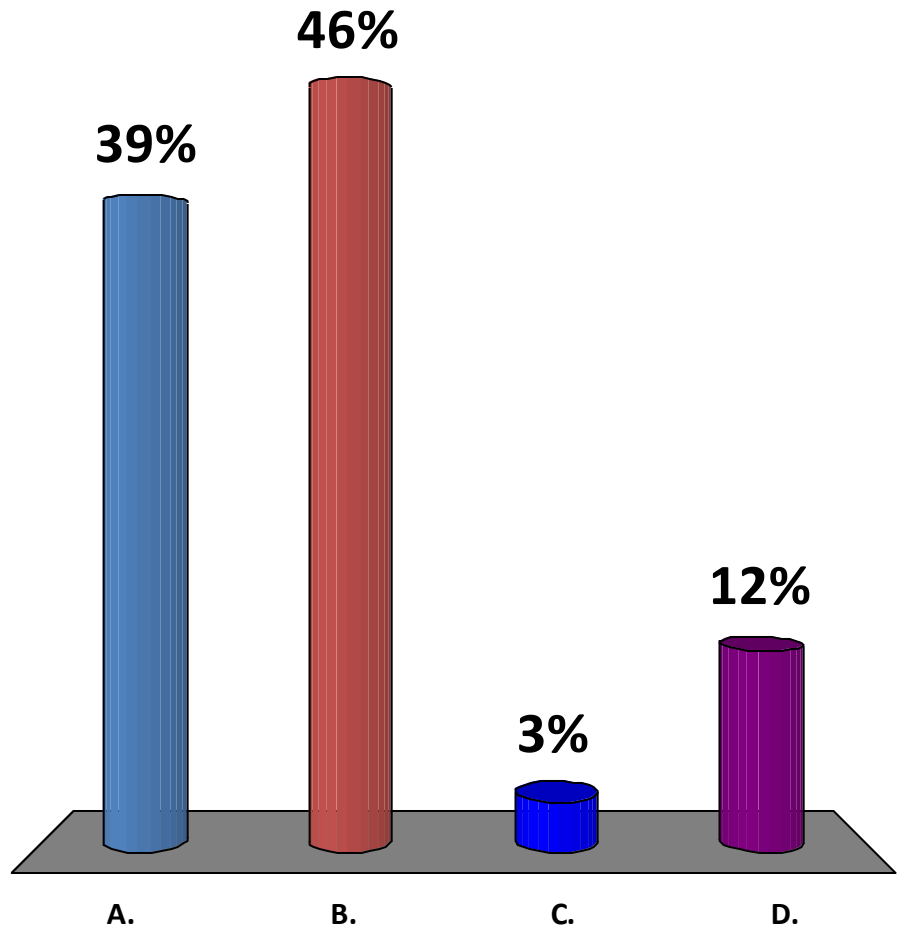


More video footage



What is the likely diagnosis?

- A. Epileptic seizure
- B. Non-epileptic attack disorder
- C. Syncope
- D. Don't know



- Diagnosing the cause of a blackout can be difficult
- You can make mistakes if you miss the start of the attack

Main differential diagnostic problem: epilepsy vs non-epileptic attack disorder (NEAD)

Diagnosis

Blackouts: a practical approach

- Get as much information as possible
- First decide: is it syncope?
- Are there features that point towards epilepsy or NEAD?
- Is it really weird?
- How do they give the history?

First decide: is it syncope?

- Prodrome
- Nausea
- Visual constriction
- Dizziness
- Short duration
- May jerk or (more rarely) wet themselves
- Rapid recovery (unless supported)

Points of history to focus on...

- Shaking: nature, amplitude, frequency, evolution
- Eyes
- Incontinence
- Cyanosis (sorry...)
- Unpleasant bites
- Responsiveness
- Estimated duration
- Speed of recovery

Epilepsy vs NEAD

Epilepsy	NEAD
Aura	Aura
Onset from sleep	Onset reported from sleep
Tonic and clonic phases	Shaking
Variation in amplitude and frequency	Seminology constant
Can be bizarre	Can be bizarre
Urinary incontinence	Urinary incontinence
Lateral tongue bite	Can bite tip of tongue
Cyanosis	Not usually
Indistinct vocalisation	Not usually
Eyes open	Eyes closed
Lasts 30 secs-2 minutes	May be prolonged or relapsing
Confused afterwards	Rapid recovery
May sleep	Tired, post-event crying
Stereotyped	Seminology variable
Sometimes	History of abuse



Conversational analysis



- Spontaneity
- Richness of detail
- Attempts at reformulation
- Concentrates on event not circumstances
- “I think its stress-related”

If still uncertain....

$$\Delta x \Delta p \geq \frac{\hbar}{2}$$

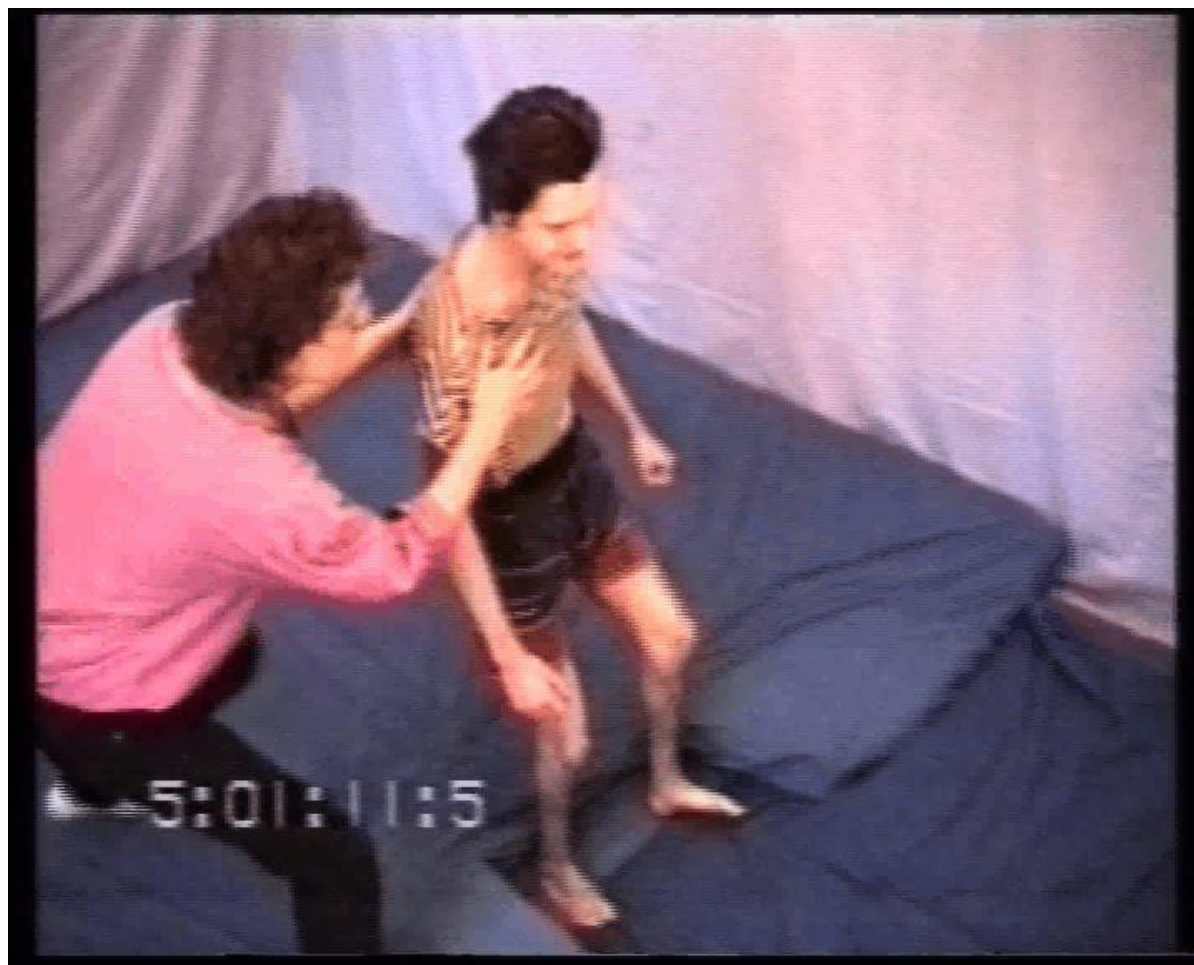- Tell the patient
- Gather more information: video on phone
- Ensure safety
- Address driving
- Review

Driving (May 2016)

- MUST inform the DVLA
- First seizure- 6-12 months
- Multiple seizures- 12 months (all types)
- Secondary causes (1 week from acute head injury or 24 hours from intracranial surgery or stroke; electrolytes; eclampsia)- individual basis
- Withdrawal- not for 6 months after last dose
- HGV-5-10 years off medication
- Syncope: **prodrome and posture**
- **Vasovagal with reliable prodrome or avoidable trigger whilst standing- OK to drive, no need to inform DVLA**
- Vasovagal syncope with prodrome/trigger while sitting: 1 month
- Unexplained syncope inc. without prodrome: 6-12 months
- Blackout with seizure markers: 6-12 months
- NEAD- 3 months without attacks
- Cough syncope- 6-12 months except if conditions fulfilled

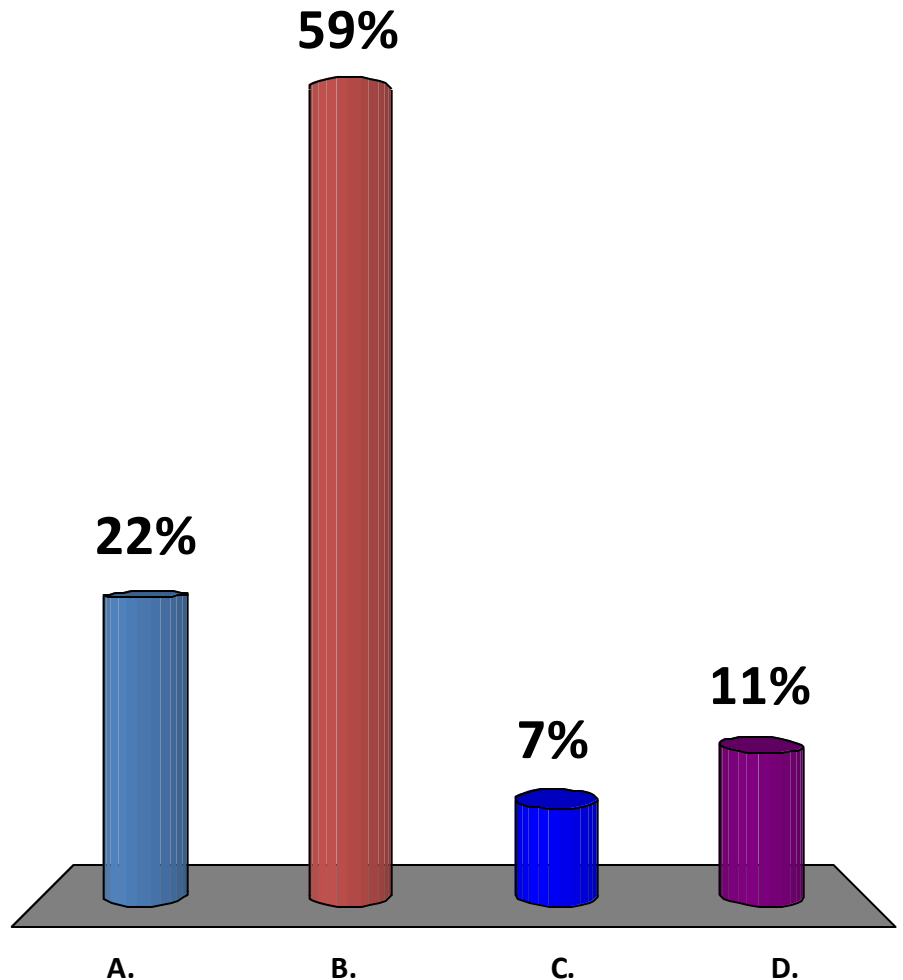
Some witnessed blackouts...

An attack



What is the likely diagnosis?

- A. Epileptic seizure
- B. Non-epileptic attack disorder
- ✓ C. Syncope
- D. Don't know



Vasovagal syncope



- Myoclonic jerks are common in vasovagal syncope

Provokation

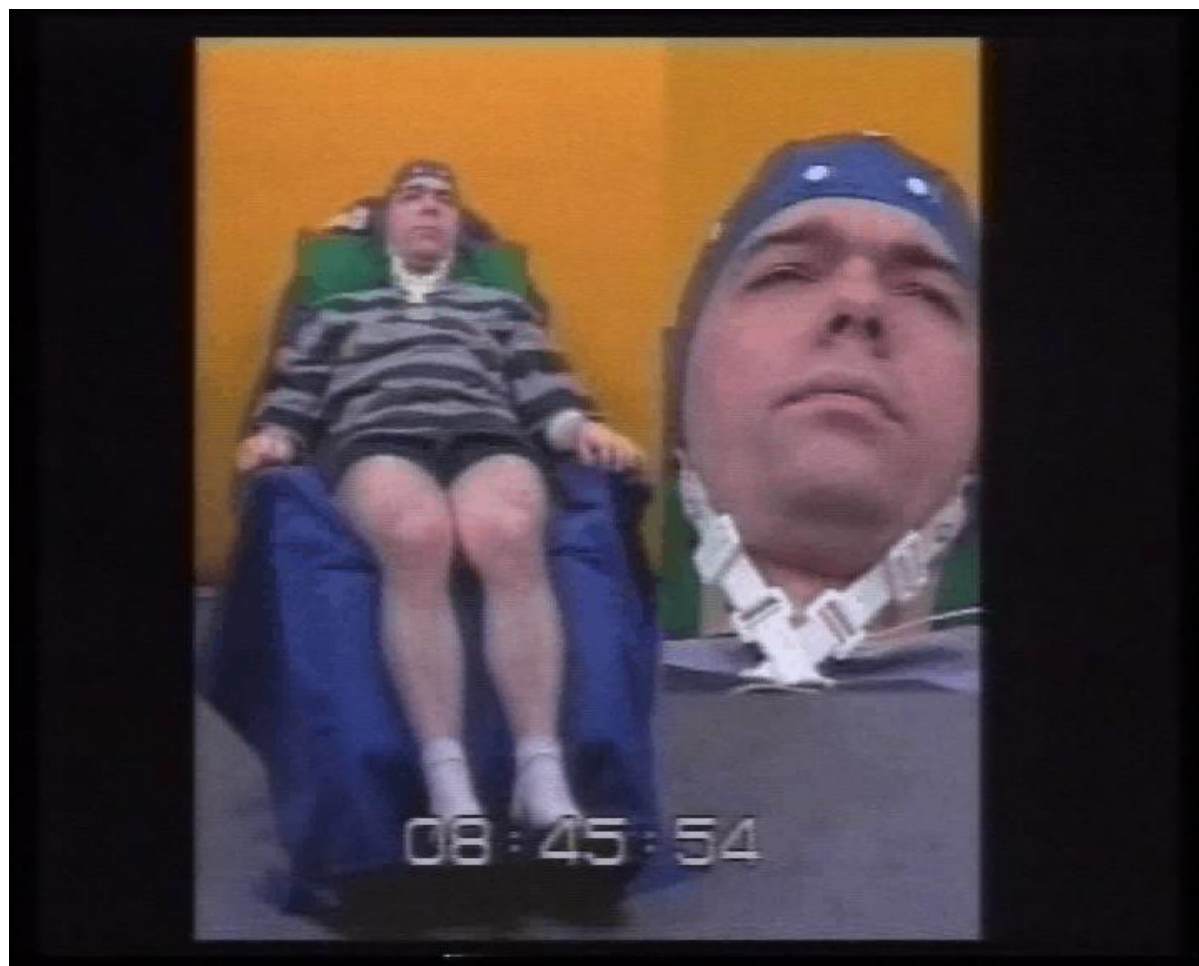Postural

Prodrome

Rapid recovery

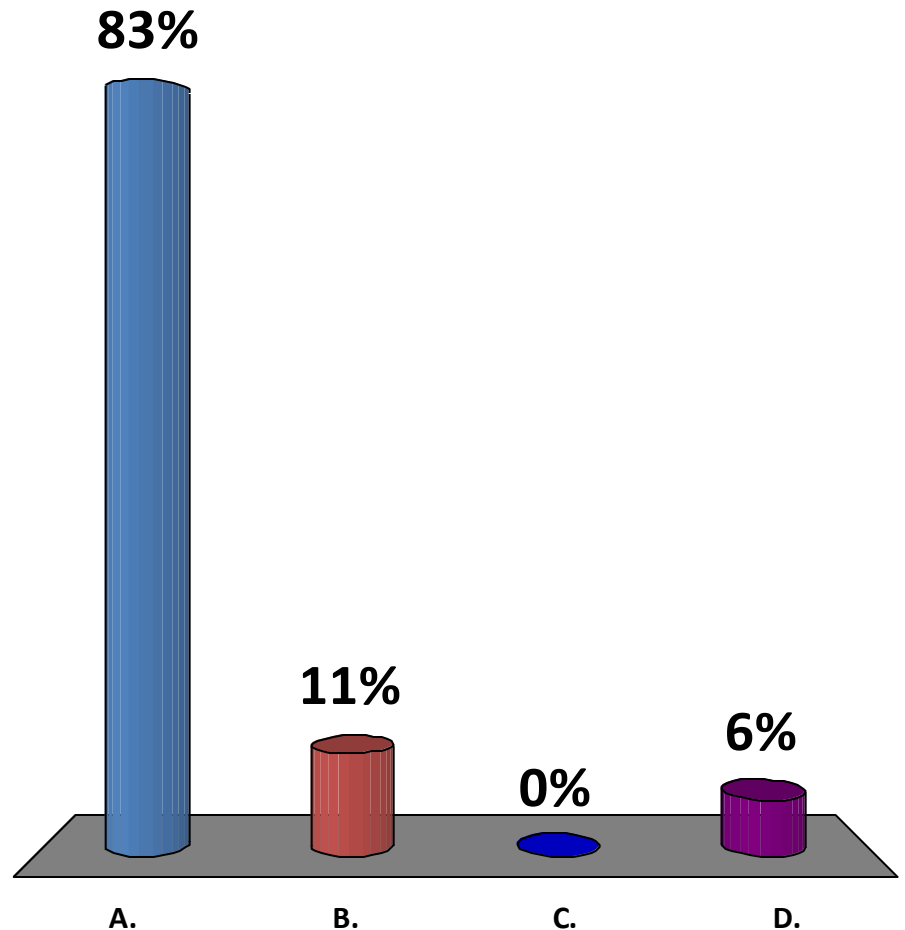
Lempert et al,
Ann Neurol 2004
12s
90% myoclonus
Head turns,
automatisms

Another attack

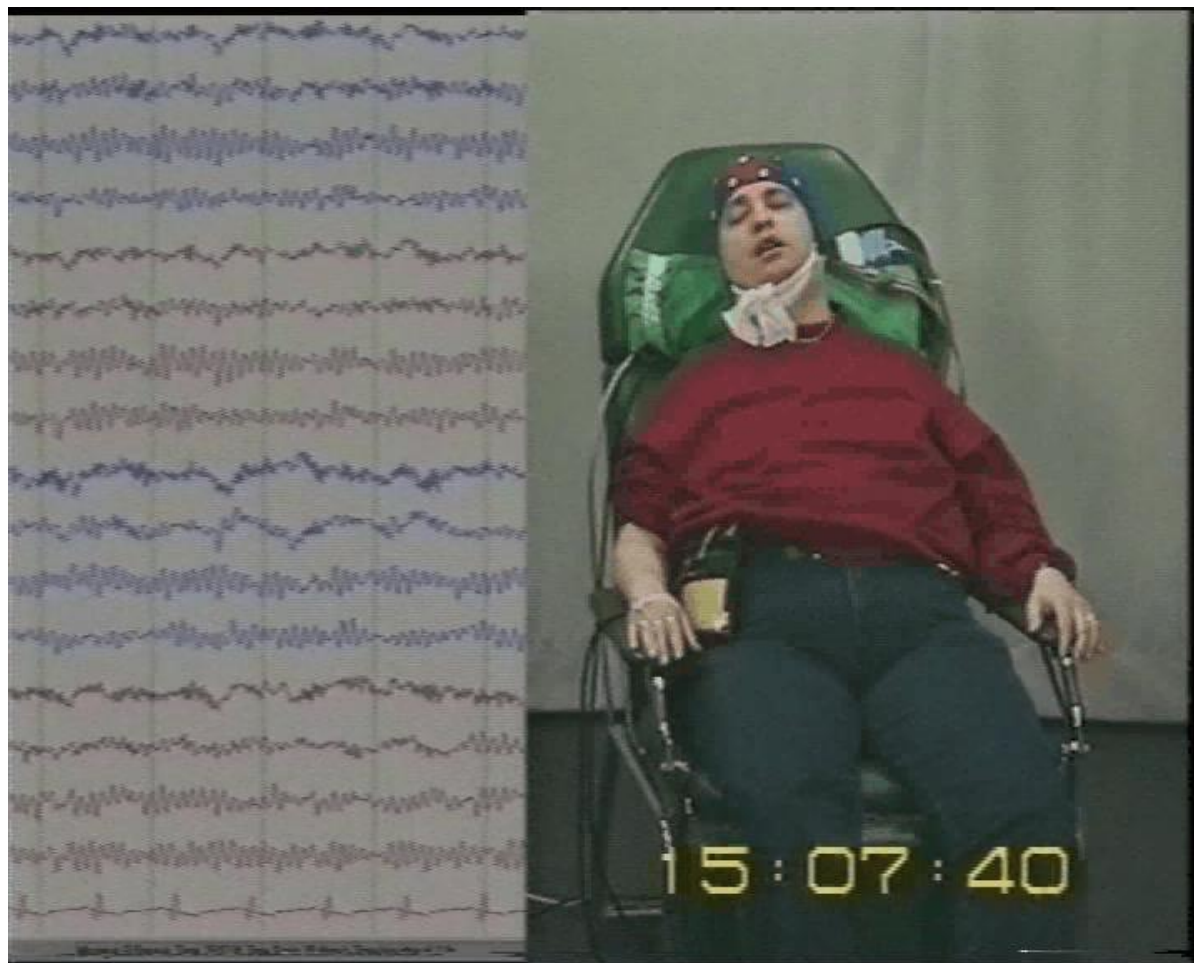


What is the likely diagnosis?

- ✓ A. Epileptic seizure
- B. Non-epileptic attack disorder
- C. Syncope
- D. Don't know

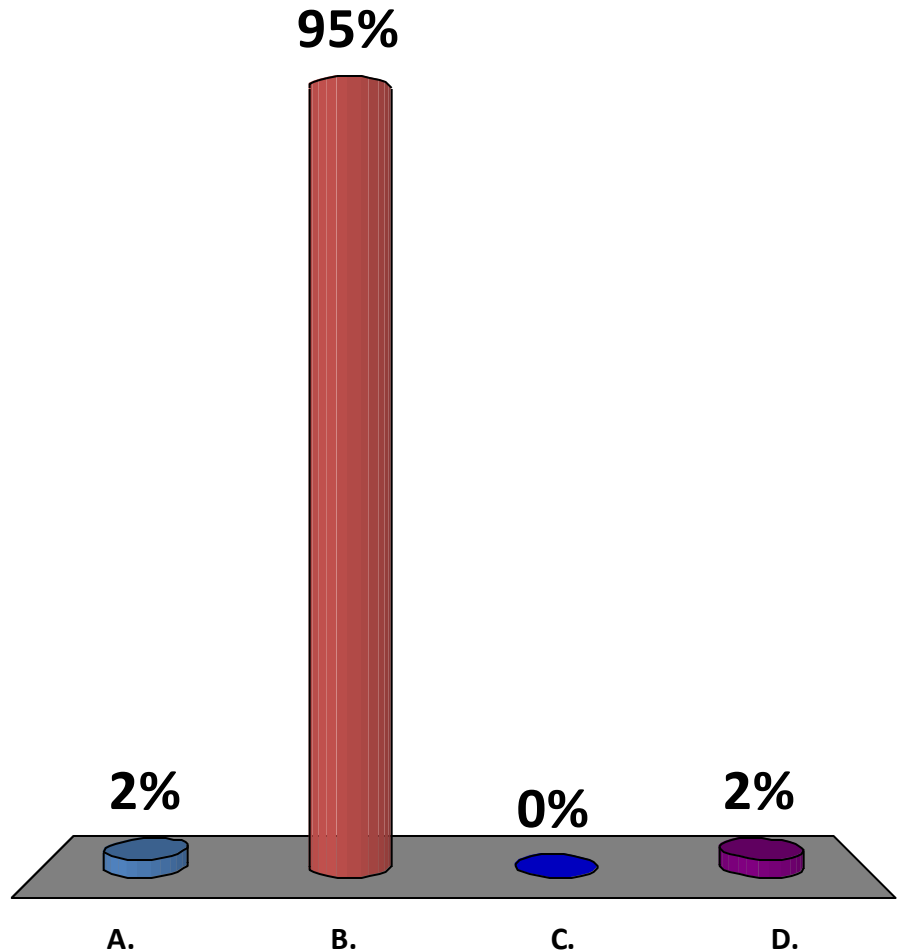


Another attack



What is the likely diagnosis?

- A. Epileptic seizure
- ✓ B. Non-epileptic attack disorder
- C. Syncope
- D. Don't know

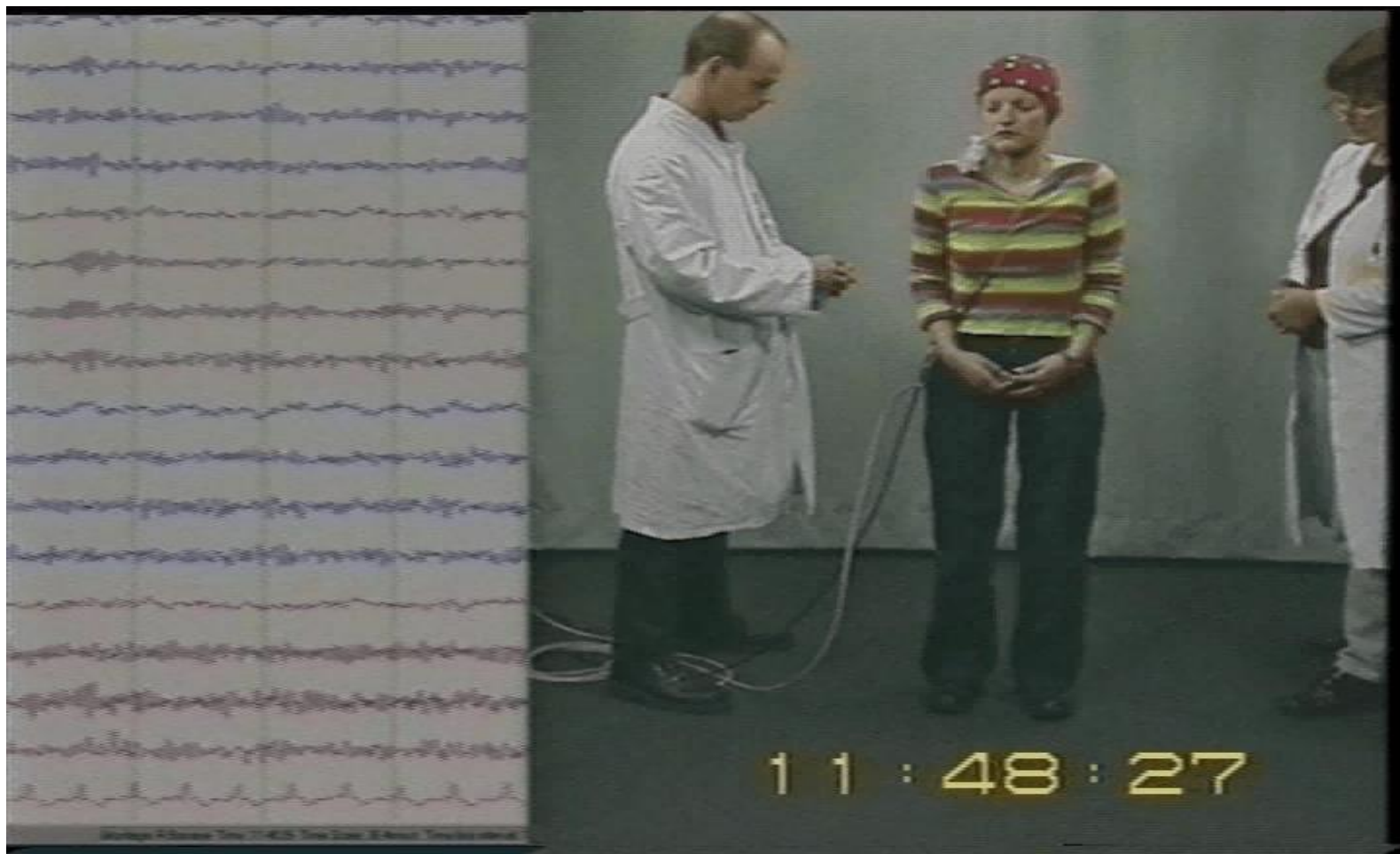


Non-epileptic attack disorder

- Eyes closed, stopping and starting, partially responsive, non-ictal semiology shaking

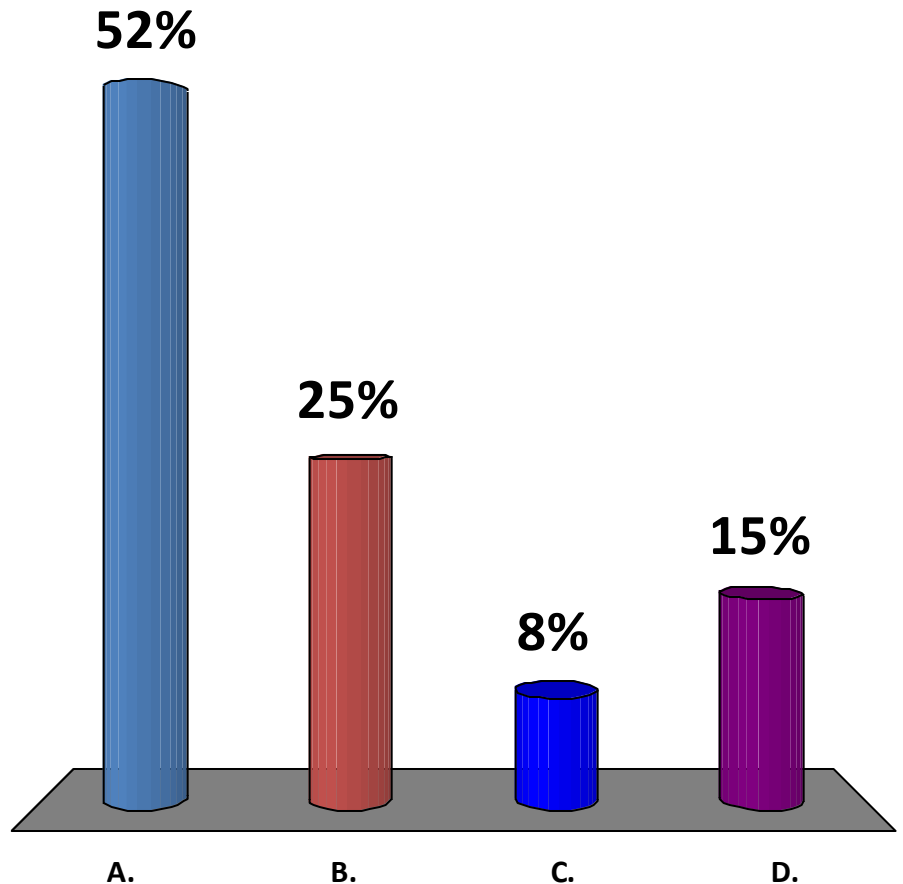


Another attack



What is the likely diagnosis?

- A. Epileptic seizure
- ✓ B. Non-epileptic attack disorder
- C. Syncope
- D. Don't know

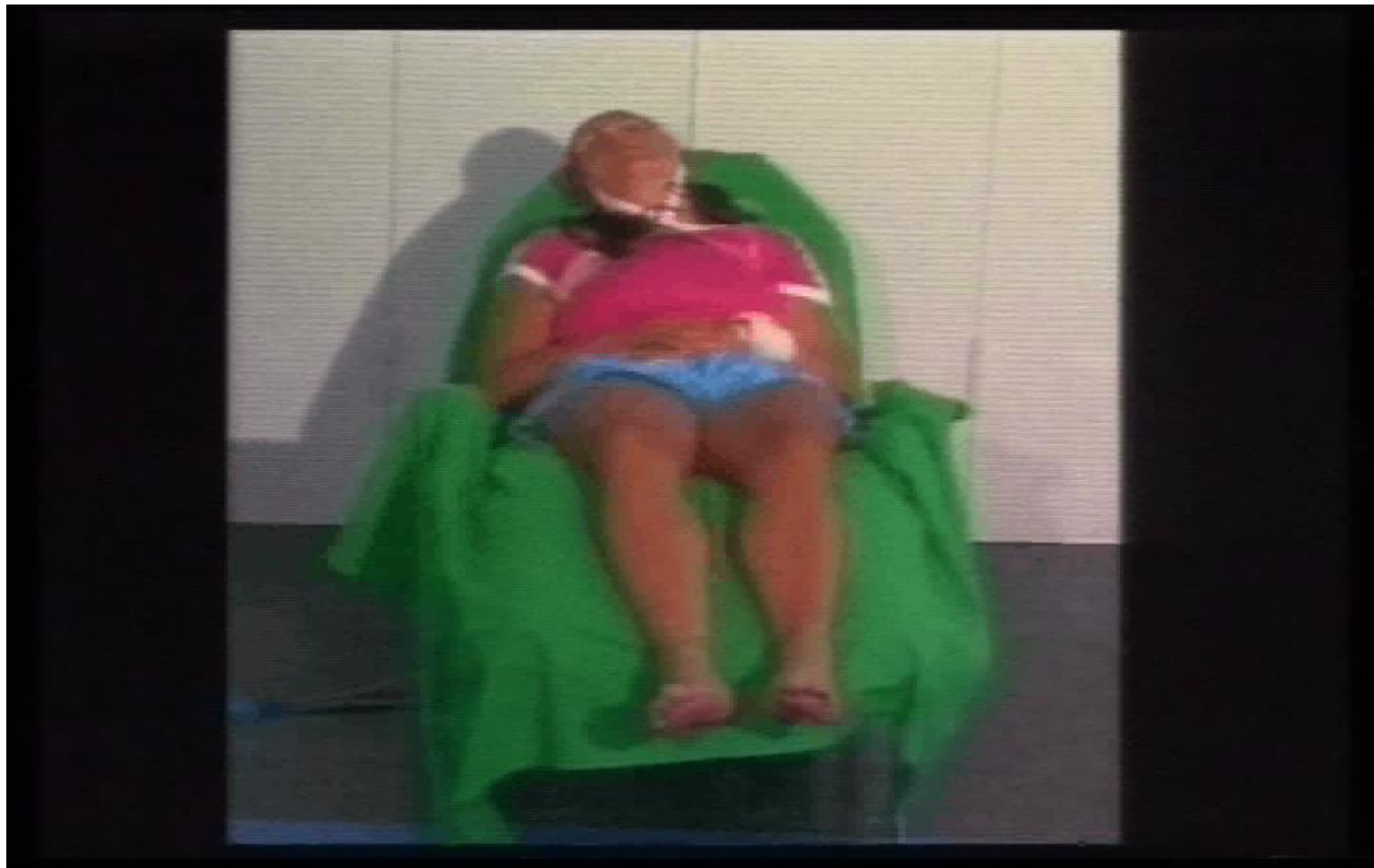

Non-epileptic attack disorder

- “Pseudo-tonic” arched posture, regular frequency and amplitude shaking, sequence wrong

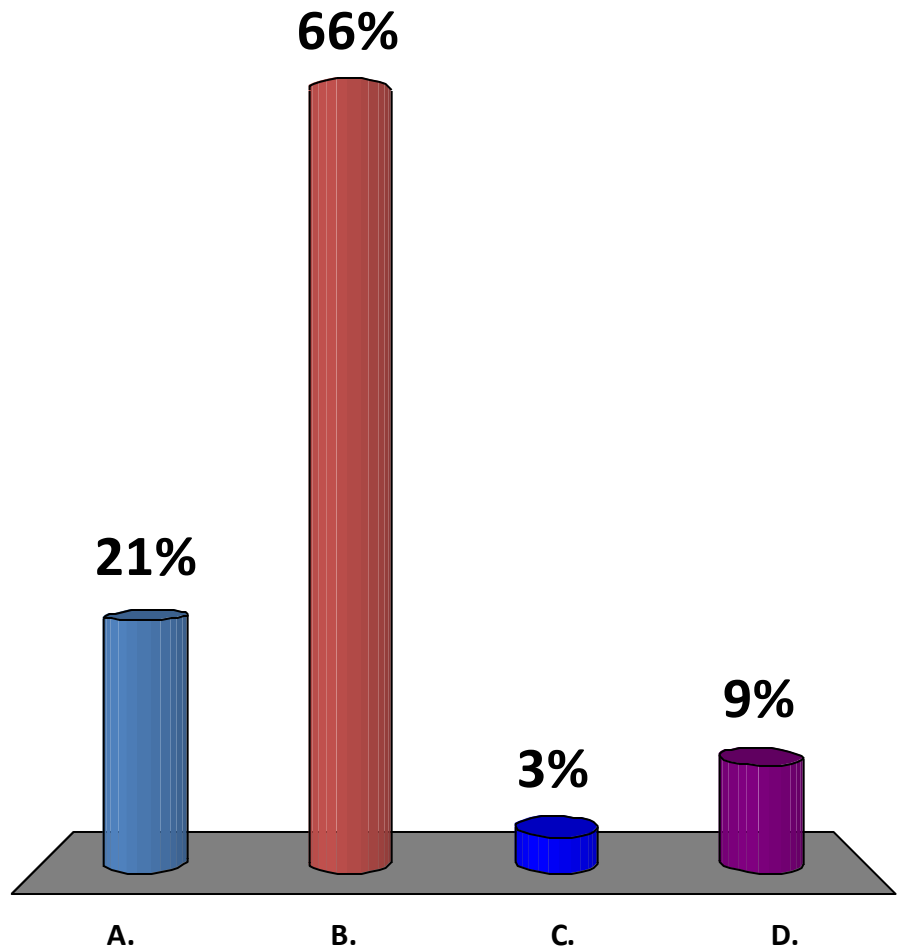


Another attack



What is the likely diagnosis?

- ✓ A. Epileptic seizure
- B. Non-epileptic attack disorder
- C. Syncope
- D. Don't know



Frontal lobe seizure

- May be bizarre but **stereotyped**
- Motor posturing or activity
- Short-lasting
- Consciousness may be retained
- EEG often normal during attack

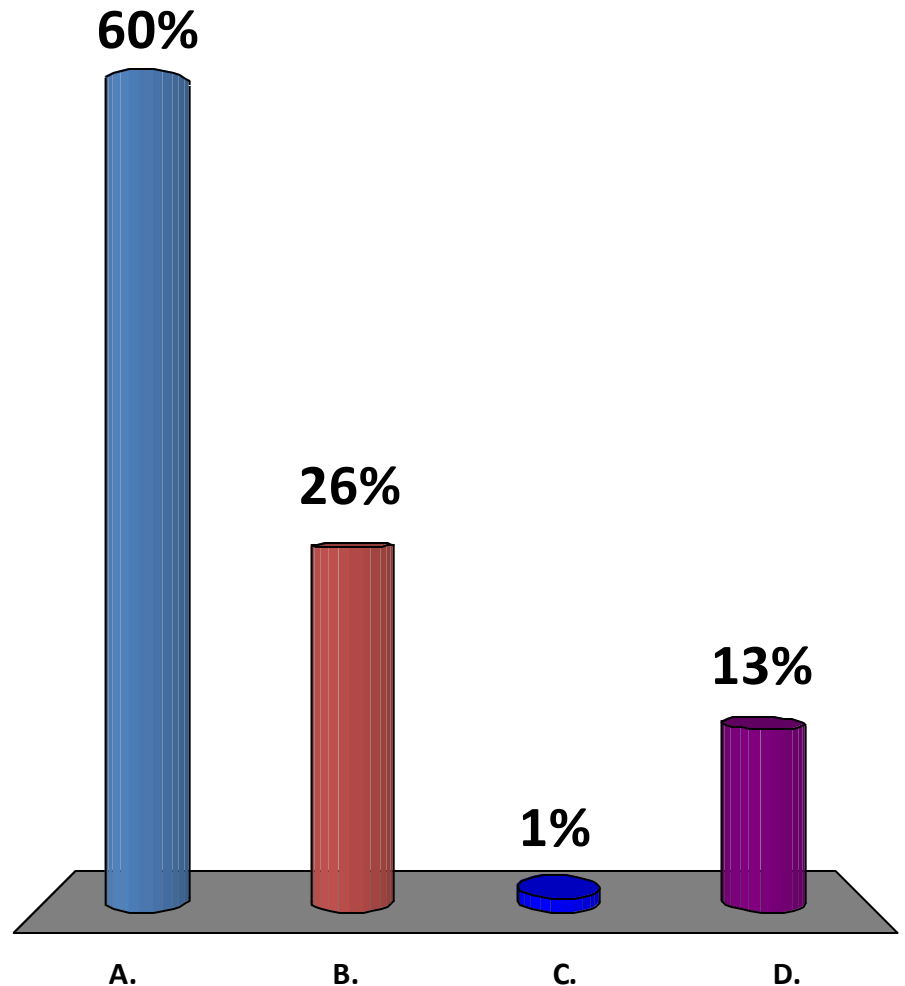


Another attack



What is the likely diagnosis?

- ✓ A. Epileptic seizure
- B. Non-epileptic attack disorder
- C. Syncope
- D. Don't know

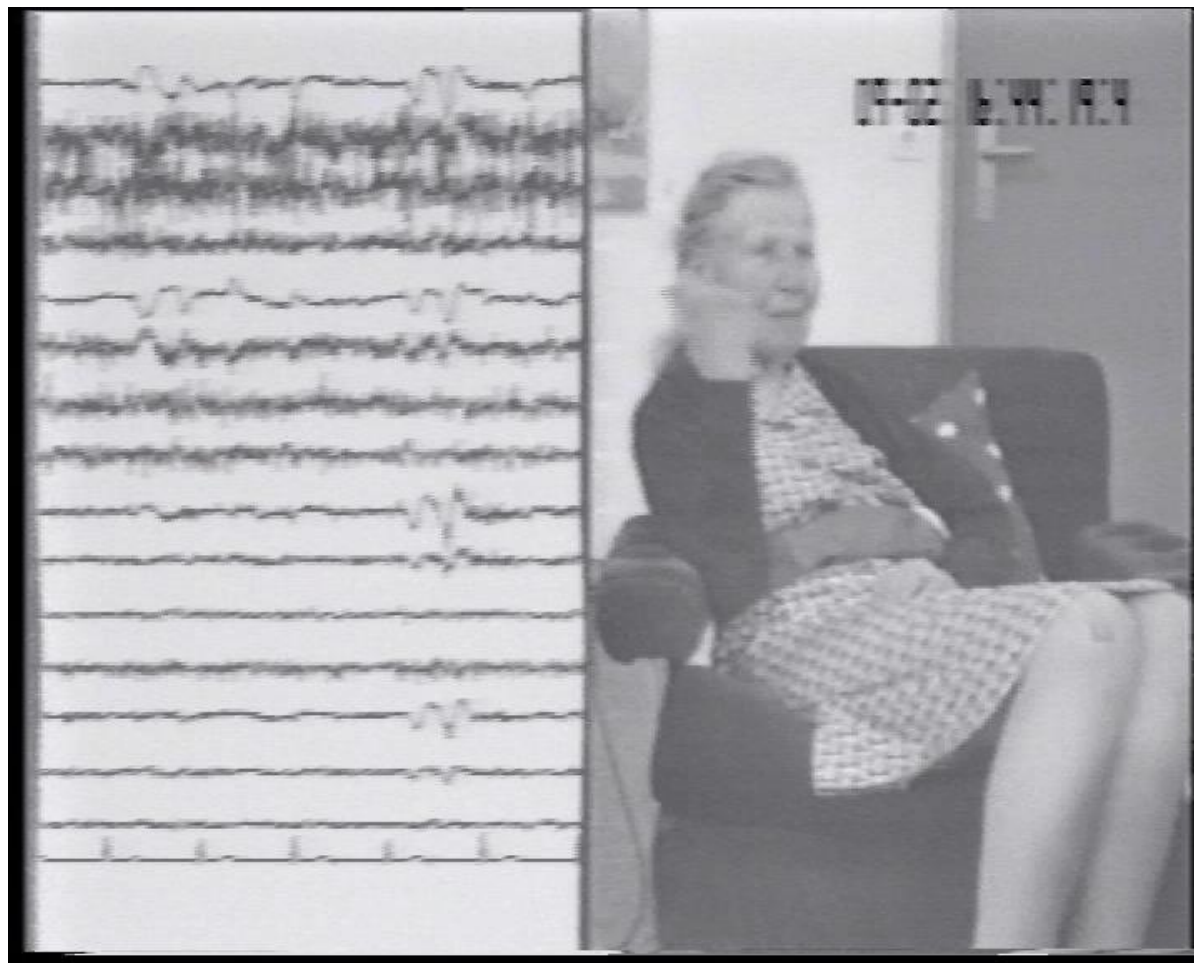


Complex partial seizure

- Not an absence
- May be aura
- Automatism
- Usually loss of awareness
- May wander around confused
- Can be atypical

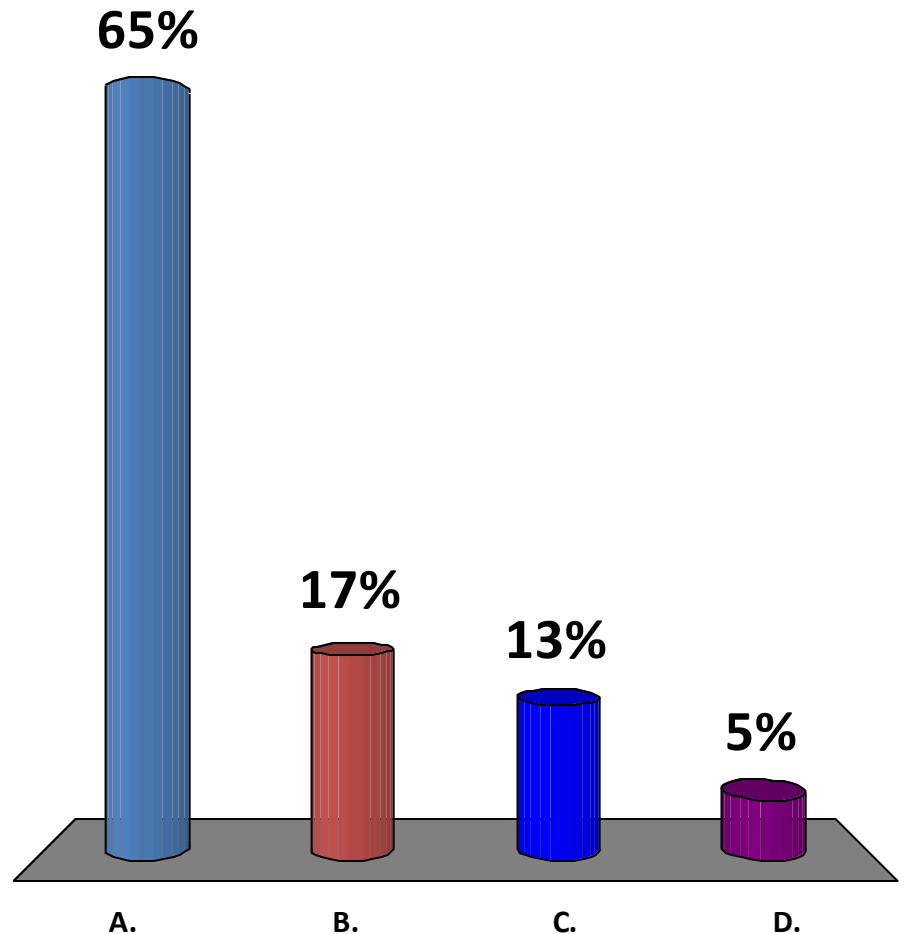


Another attack



What is the likely diagnosis?

- A. Epileptic seizure
- B. Non-epileptic attack disorder
- ✓ C. Syncope
- D. Don't know



Cardiac syncope: two groups

- YOUNG PATIENTS
- Long QT
- WPW
- Brugada
- Arrhythmogenic right ventricular cardiomyopathy
- HOCM
- OLDER PATIENTS
- IHD
- Heart block

History

- A 21yr woman awoke her boyfriend in the early hours one morning when they were both sleeping.
- Her breathing was erratic, her body stiff, her eyes open and she was unresponsive for 2–3 min.
- She did not have tonic or clonic movements, tongue biting or incontinence.
- She was drowsy and amnesic for the event.
- She was taken to an A&E department.
- Examination was normal

ECG

21 years Female Caucasian
Vital rate 53 bpm
PR interval 150 ms
QRS duration 88 ms
QT/QTc 406/427 ms
P-R-T axis 49 57 39

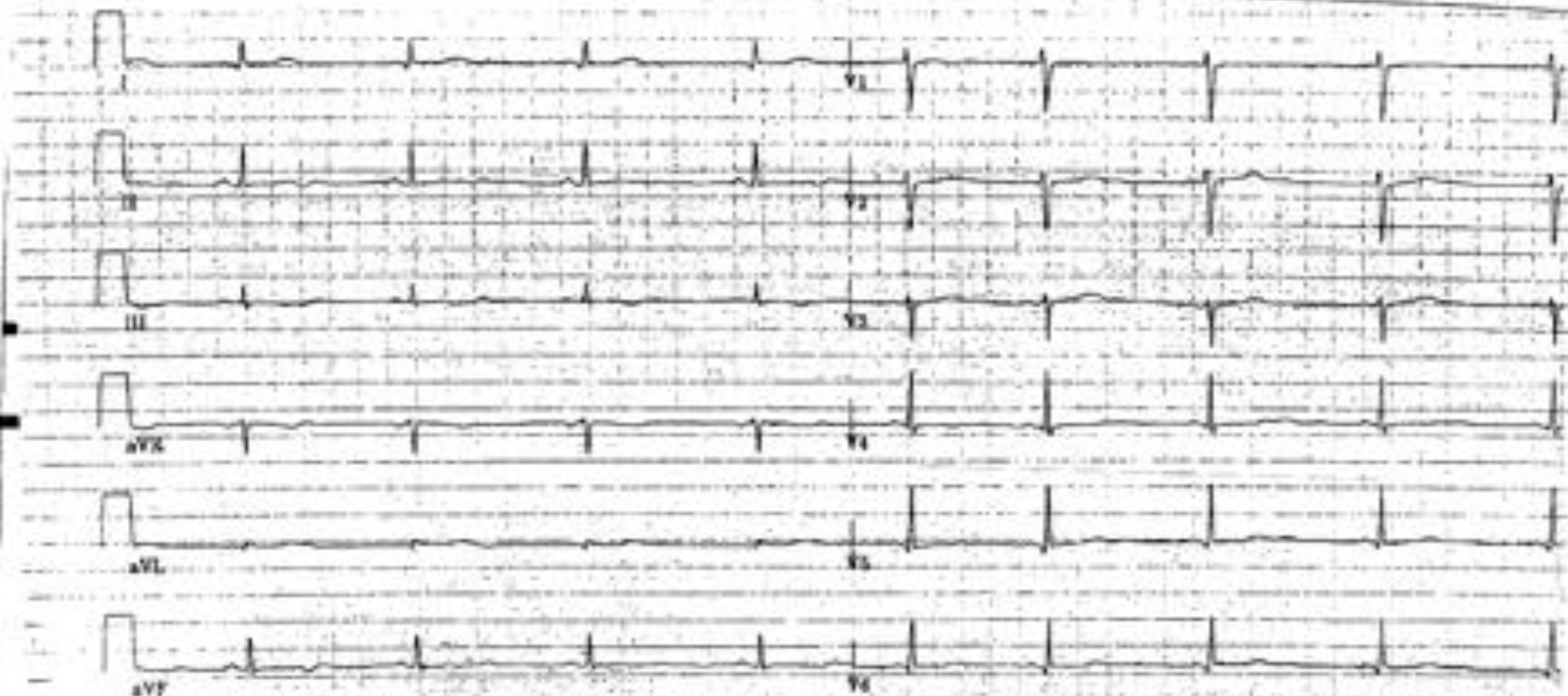Some bradycardia with sinus arrhythmia
Otherwise normal ECG

Resp: AMAU

Technician: JA
Traf: 106 COLLAPSE

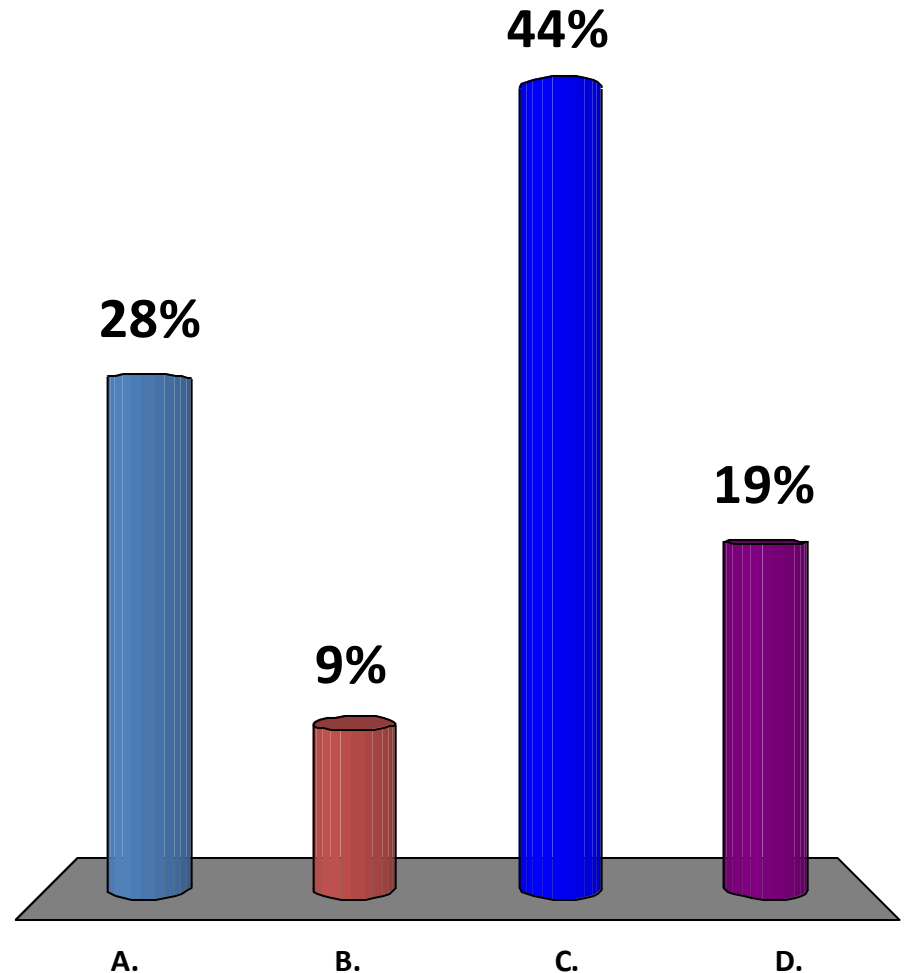
Referred by: ERSA, AMAU

Unidentified



What is the likely diagnosis?

- A. Epileptic seizure
- B. Non-epileptic attack disorder
- C. Syncope
- D. Don't know



History

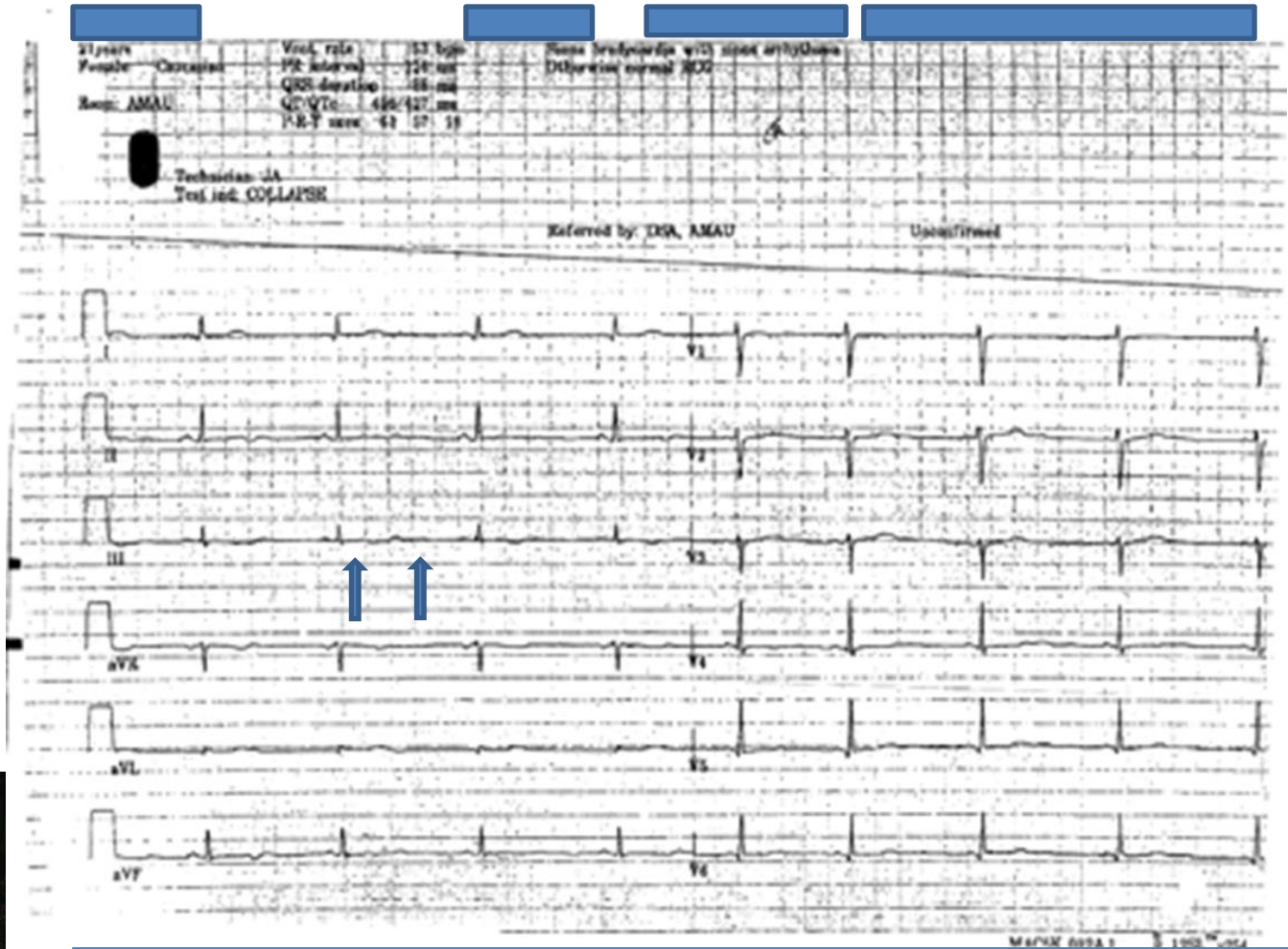
- She was seen in clinic 4 weeks later.
- There had been no further symptoms and no relevant history could be added.
- There was clinical uncertainty about the nature of the attack but it was felt most likely that an event arising from sleep could be a seizure.
- A standard EEG and an MR brain scan were both reported as normal.

History

- She was found at home dead in her bed.

Prolonged QT interval

$$QT = QTc / \sqrt{RR}$$



“It is difficult to interpret the A&E ECG and the machine has miscalculated QT and QTc, but there is undoubted QT prolongation. Some QT intervals are almost 600 ms.”

- The ECG can miscalculate QT intervals
- The prolonged QT interval is sometimes not seen in all leads

Summary: diagnosis

- Can be difficult
- Commonest differential of epilepsy is NEAD, cardiac differentials can be critical
- Take opportunities to document events in detail
- Always do an ECG
- Misdiagnosing NEAD has a morbidity too

Management

Management of epilepsy

- Non-emergency
- Type of seizures
- Type of patient

Management

- Driving
- Safety: bathing, heights, hot water
- Do they need treatment?
- Risks (further seizures, SUDEP, etc. vs spontaneous resolution, side effects, etc.)

MailOnline



[Home](#) [News](#) [U.S.](#) | [Sport](#) | [TV&Showbiz](#) | [Femail](#) | [Health](#) | [Science](#) | [Money](#) | [Video](#) | [Cof](#)

[News Home](#) | [Arts](#) | [Headlines](#) | [Pictures](#) | [Most read](#) | [News Board](#)

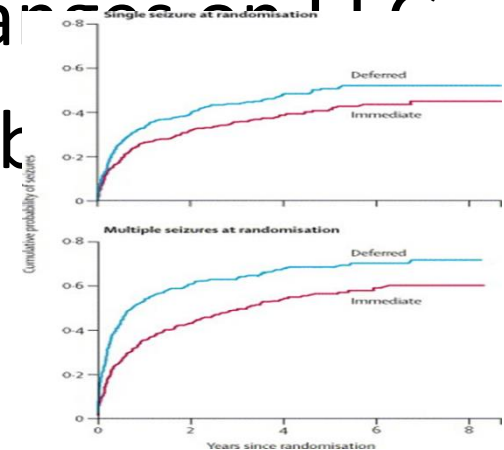
Epilepsy sufferer who refused to stop driving after being diagnosed with condition killed passenger in crash when he had fit at the wheel

Why do we not always treat after a single seizure?

- Previous myoclonic seizures or absences
- Congenital neurological deficit
- Unequivocal epileptiform changes on EEG
- Risk of recurrence unacceptable

First seizure trial group, Neurology, 1993

Risk of recurrence @ 2 years 51% untreated

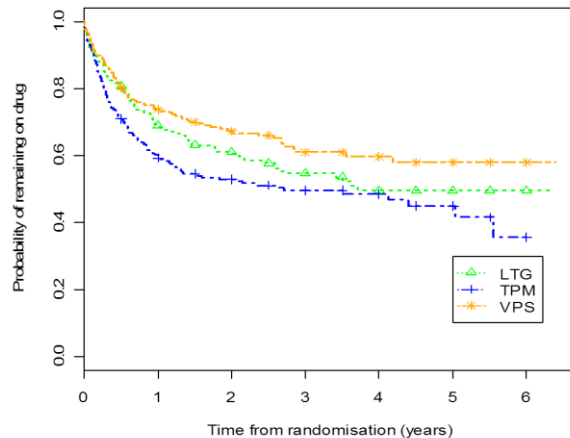


MESS study, Marson et al, Lancet, 2005
Early treatment reduces early seizure recurrence but not long-term remission rates

Which drug?

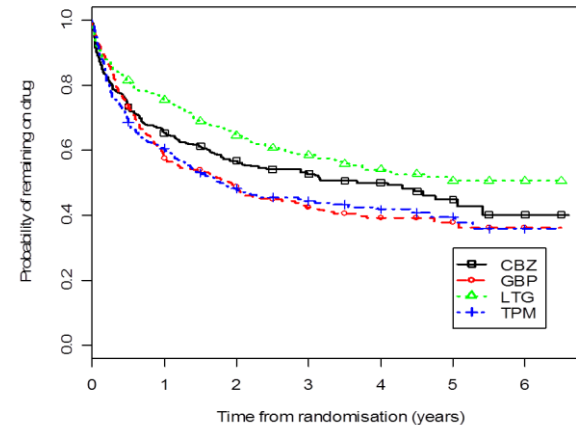
IGE

- Valproate in men
- Lamotrigine
- Levetiracetam



Focal epilepsy

- Carbamazepine
- Lamotrigine
- Levetiracetam



SANAD trial, NEJM, 2007

Clinical caveats: Carbamazepine makes myoclonic and absence seizures worse; LTG not very good for myoclonus; Levetiracetam not very good for absences

8 “C”s in the refractory patient

- Correct diagnosis?
- Correct classification?
- Correct drug?
- Covert lesion?
- Compliance?
- Comorbidity?
- Clear triggers?
- Consistent with truth?

Management options

- Identify cause
- Increase dose(s)
- Change drug(s)
- Short-term cover options

Kwon-Brodie
data, NEJM
1st drug: 50%
2nd drug 13%
3rd drug 5%

Nelligan et al, 8%
with each new
drug

Summary: management

- Is it epilepsy?
- Anticonvulsants not generally indicated after first event
- Think about the type of patient and the type of seizure

Thank you

Any questions?